

بِسْمِ اللَّهِ الرَّحْمَنِ الرَّحِيمِ

X-ray Signs Collection “I”

www.learningradiology.com

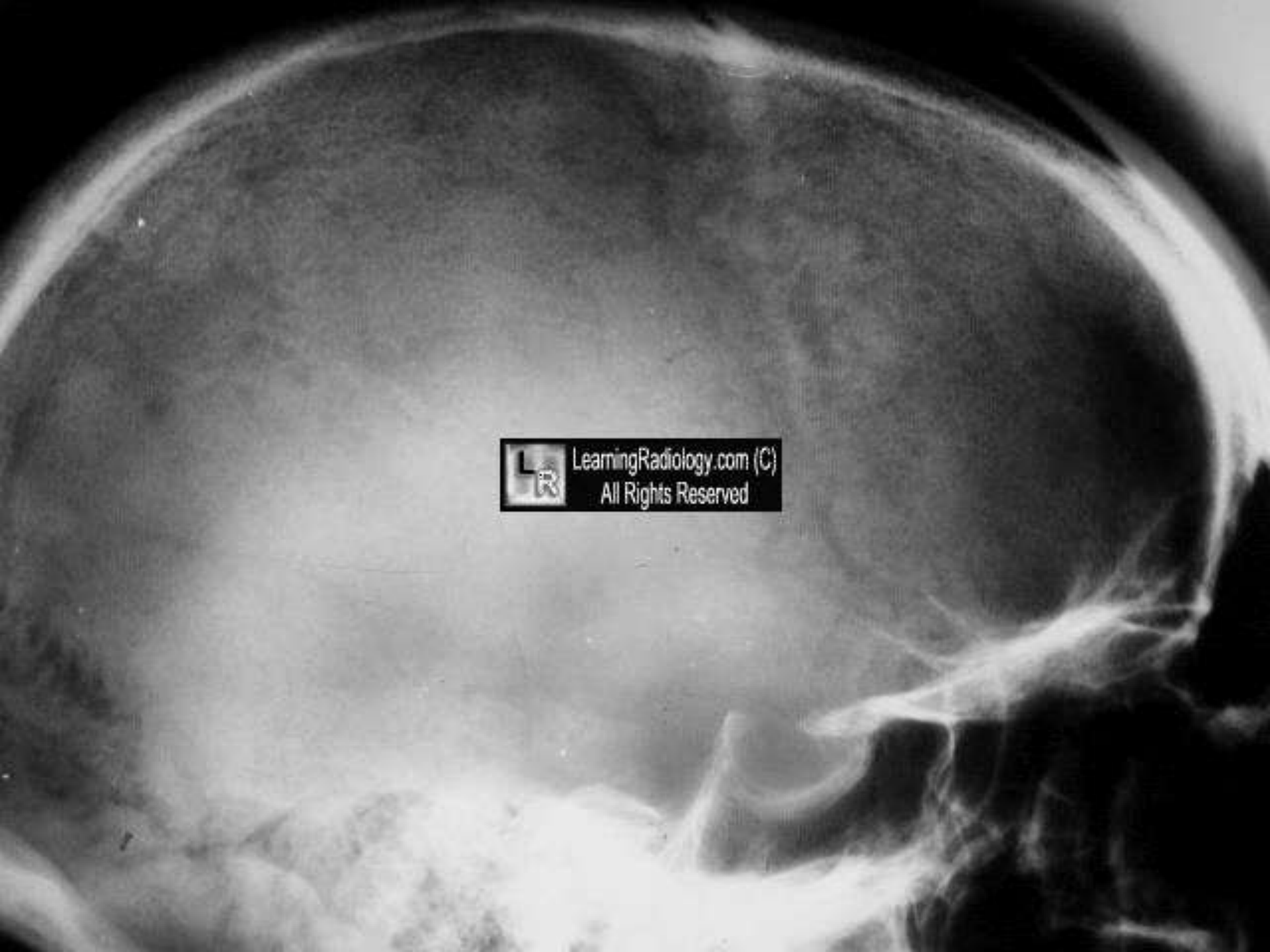
By

Ahmad Mokhtar Abodahab

Ass.Lect. Radiology Department

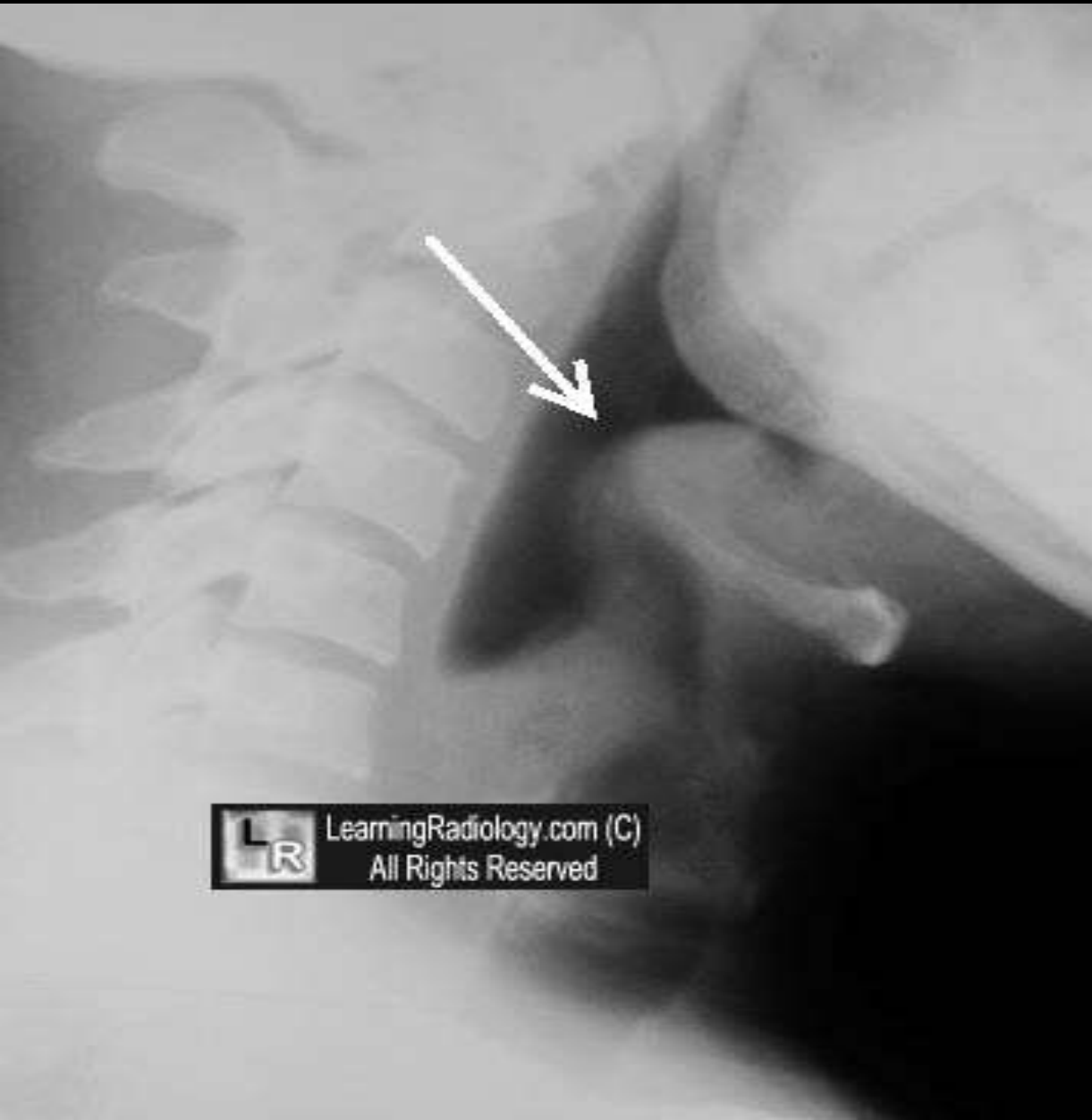Salt and Pepper Skull

- multiple, small areas of resorption of skull in
- Hyperparathyroidism
- results in mottled appearance like *salt and pepper*



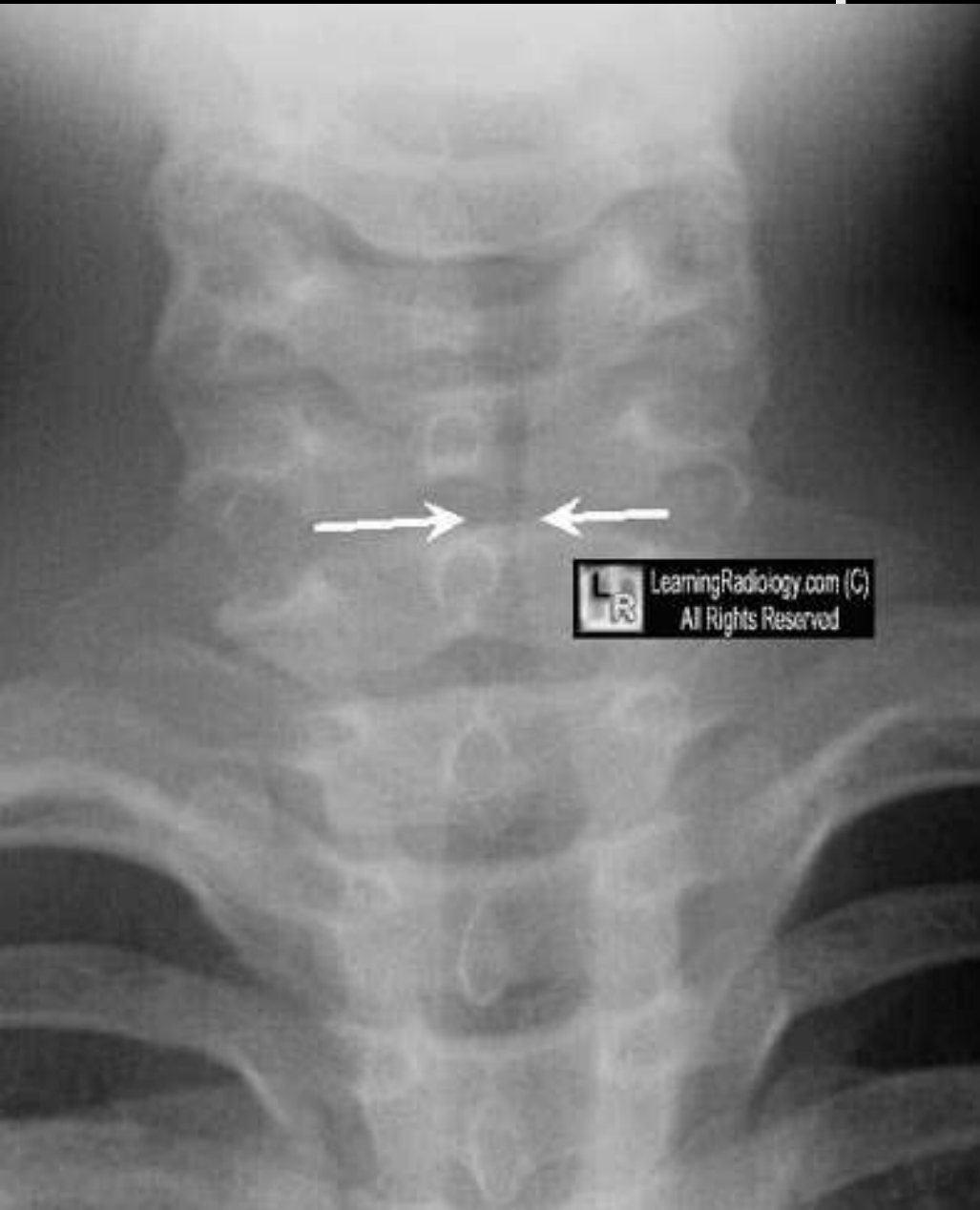
LearningRadiology.com (C)
All Rights Reserved

Thumb Sign



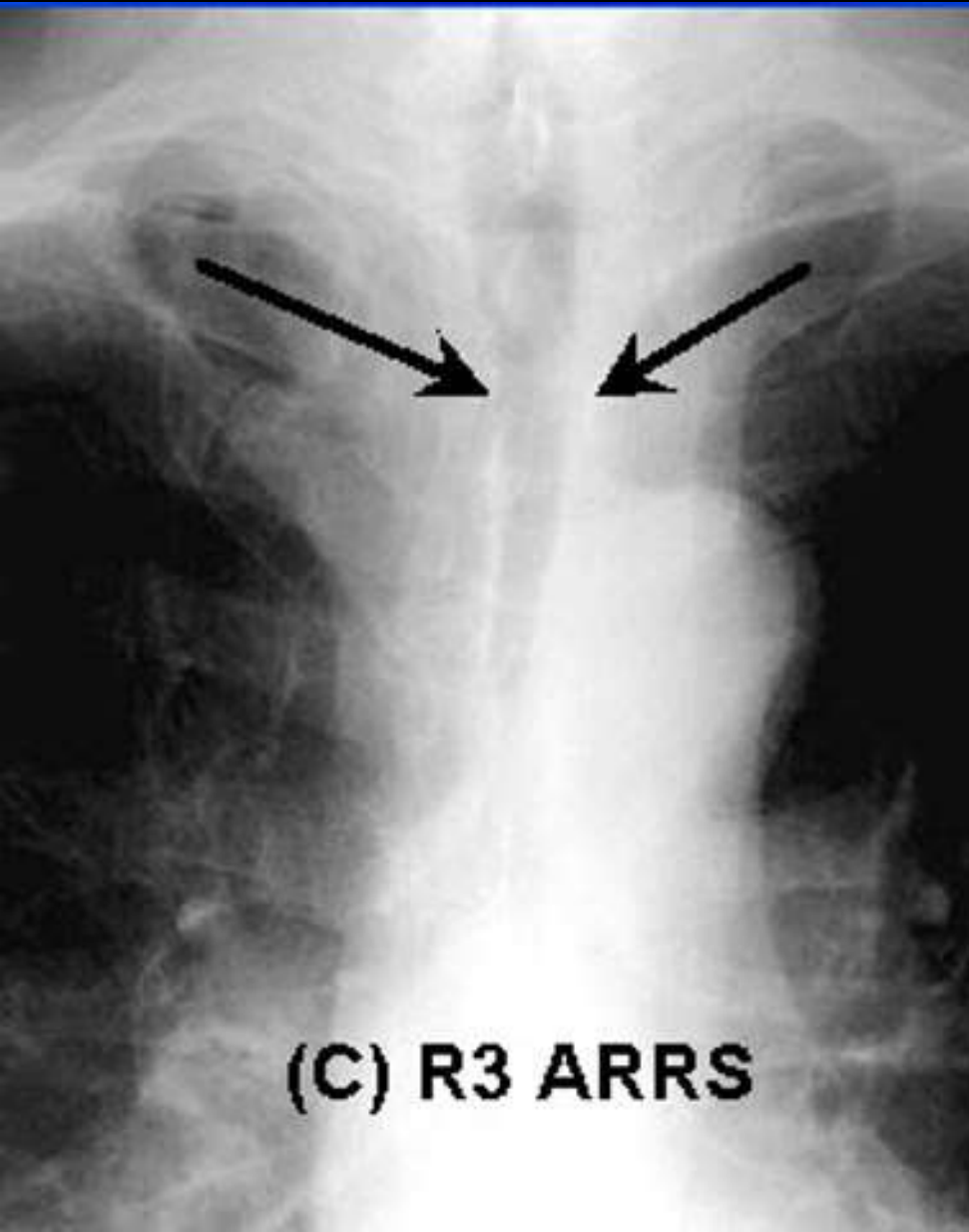
- Epiglottitis
- enlarged epiglottis,
- Instead of its usual thin fingerlike projection, → is stubby, like the thumb

Steeple Sign



- Croup
- smoothly tapered air shadow seen at level of larynx
- on AP chest or neck
- because of subglottic swelling
- Steeple = برج الكنيسة

Saber Sheath Trachea



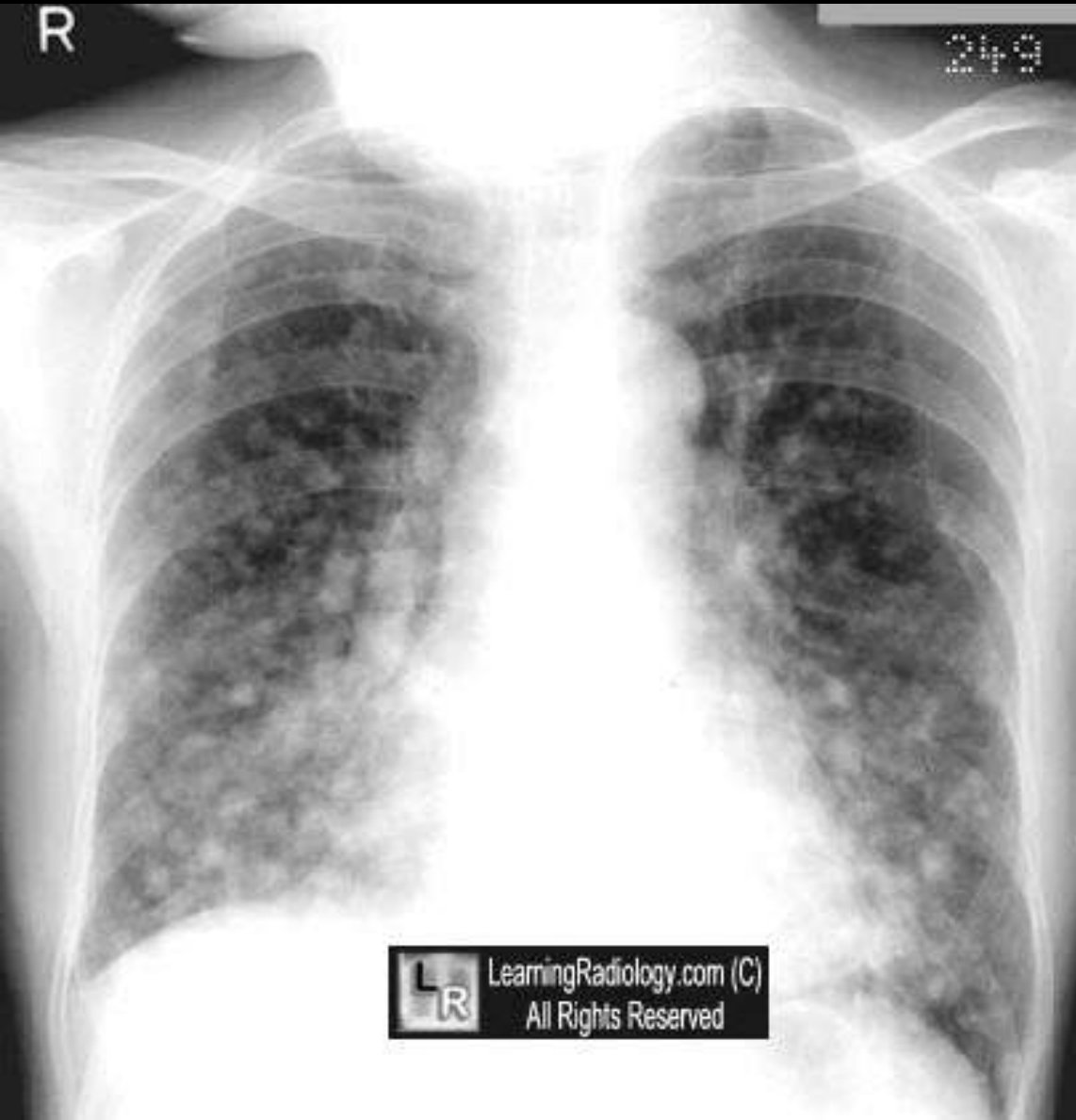(C) R3 ARRS

- marked coronal narrowing & sagittal widening of intrathoracic trachea,
- esp in COPD



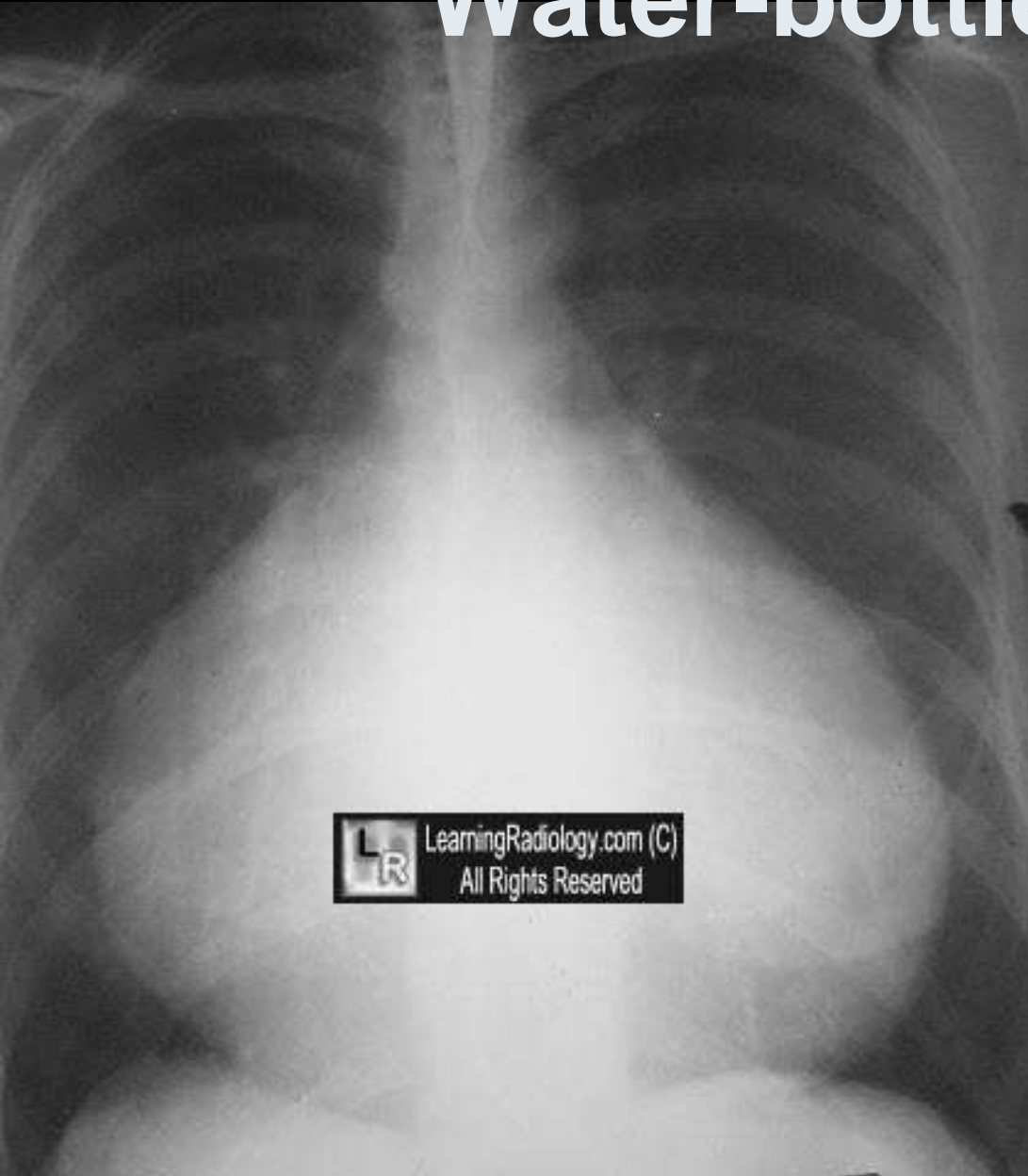


Snowstorm Appearance



- innumerable small pulmonary nodules
- frequently associated with metastatic *carcinoma from thyroid*

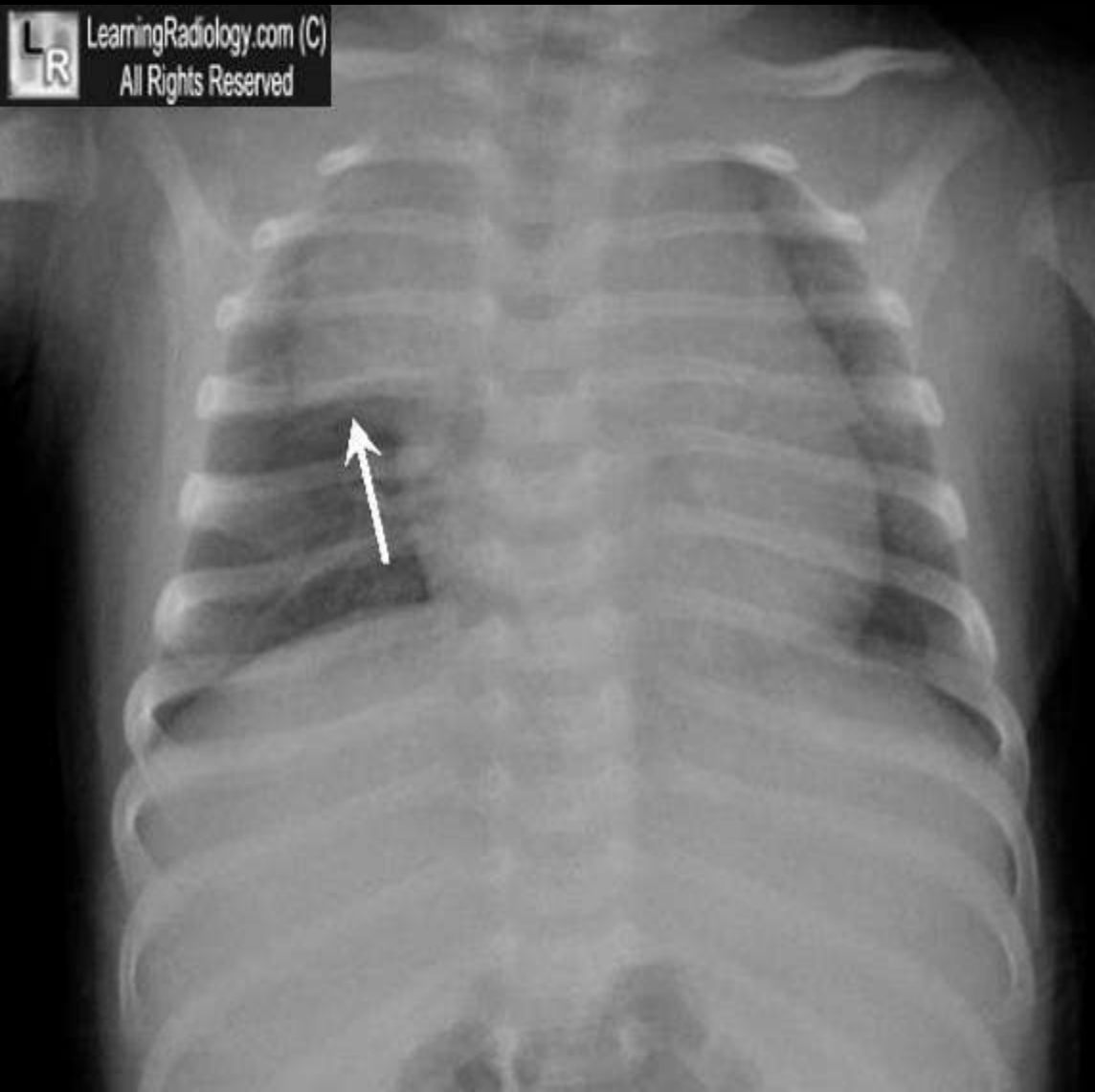
Water-bottle Heart



- globular shape of heart
- Large pericardial effusion

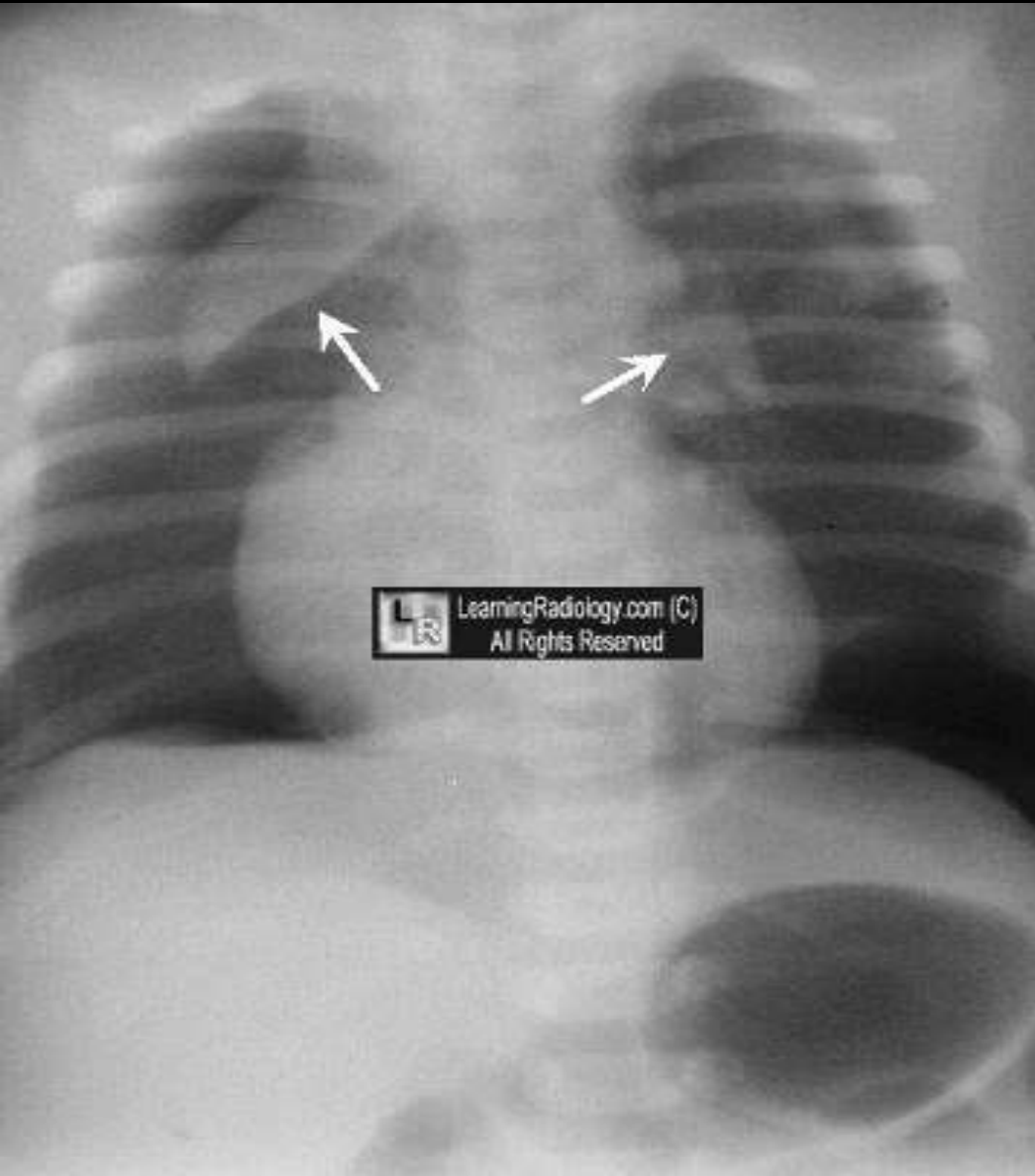
Thymic Sail Sign

LearningRadiology.com (C)
All Rights Reserved



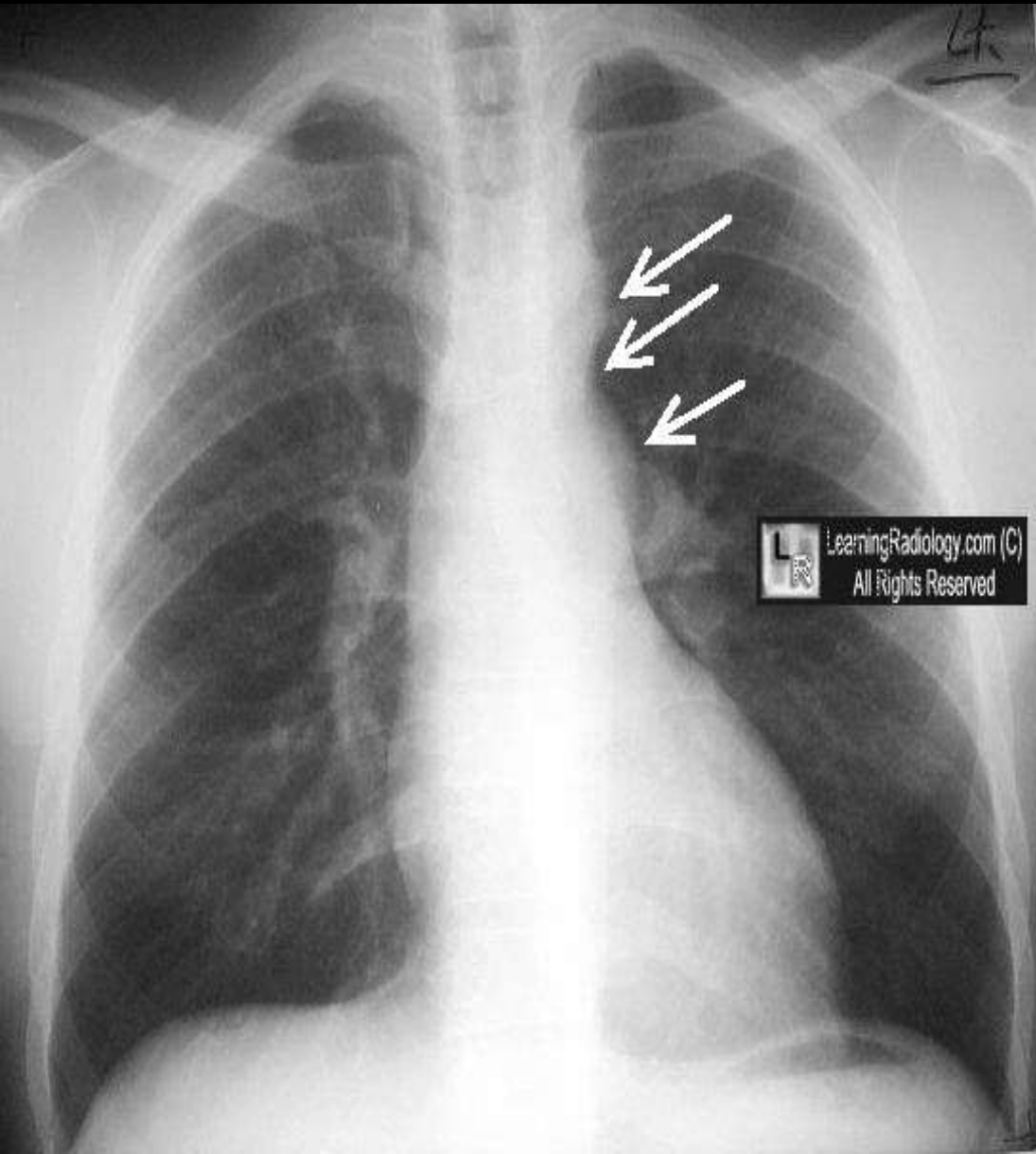
- **normal appearance of thymus gland as it contacts minor fissure;**
- **spinnaker sail sign is abnormal**

Spinnaker Sail Sign



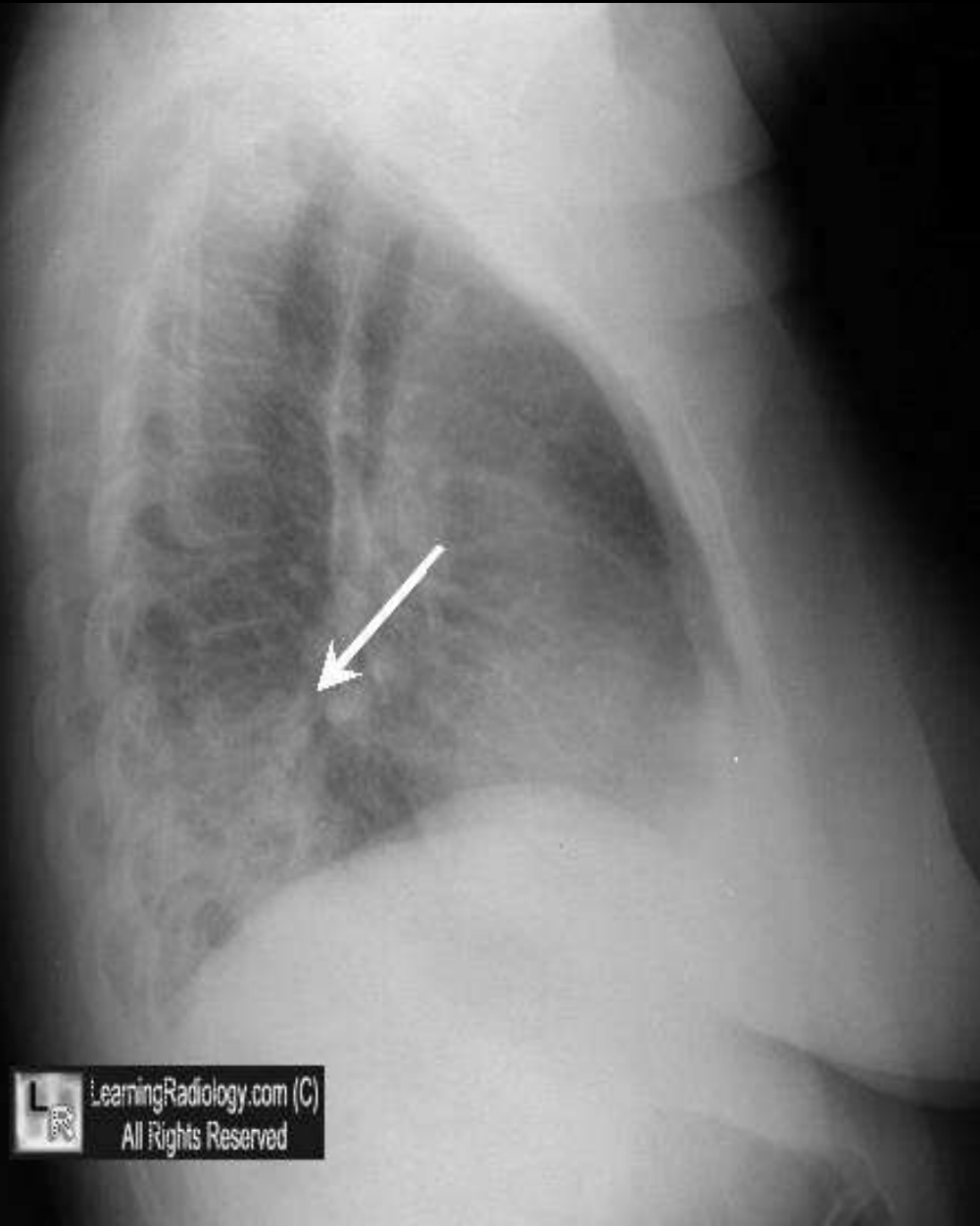
- شراع مثلث ضخم
- Abnormal elevation of lobes of the thymus
- seen with pneumomediastinum;
- thymic sail sign is normal

(cardiac)Three Sign



- Appearance of aorta, coarctation and post-stenotic dilatation
- in a coarctation of the aorta

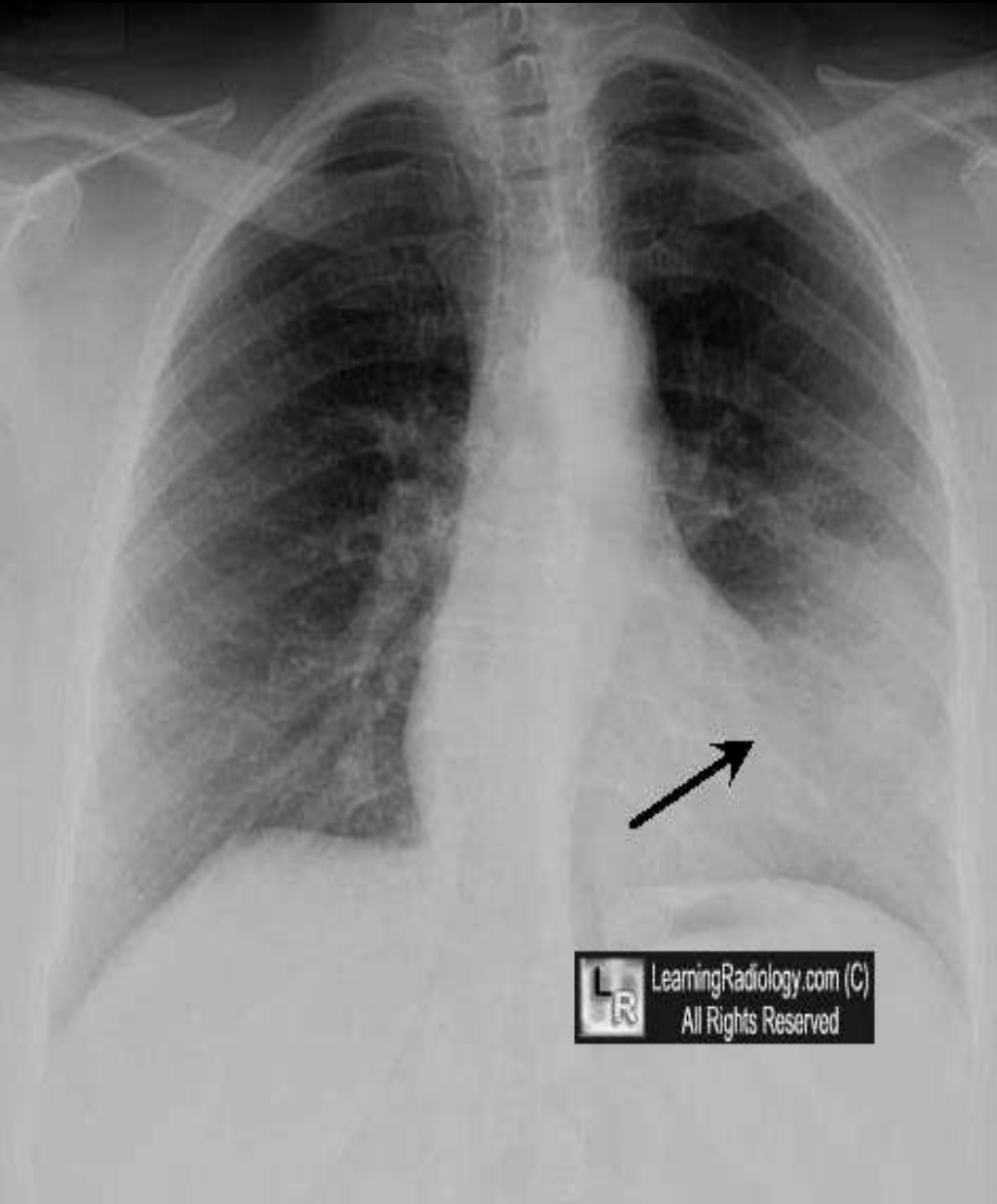
Spine Sign



- seen on lateral chest x-ray
- paradoxically increased density of lower spine
- indicative of a lower lobe process such as pneumonia

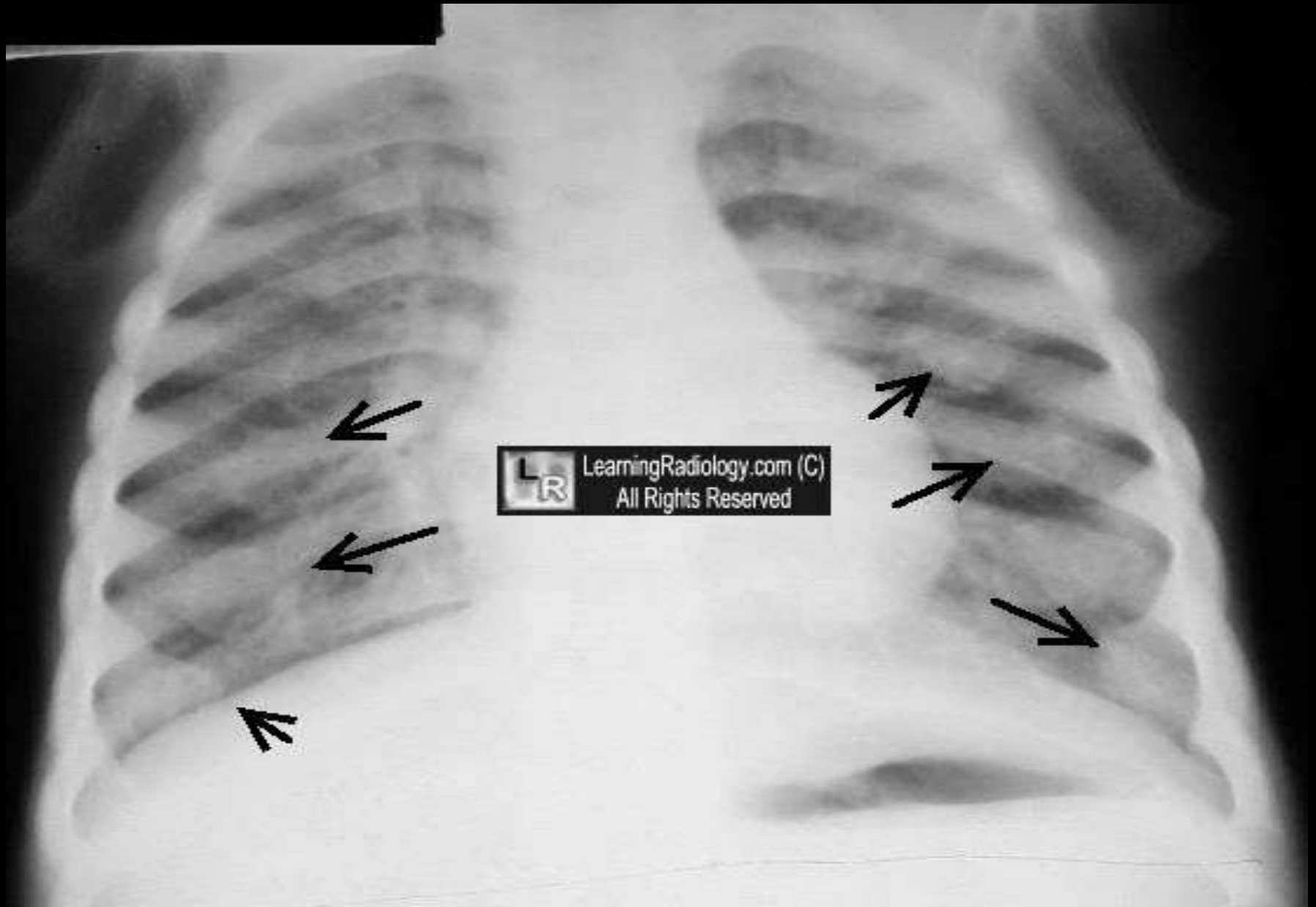



Silhouette Sign



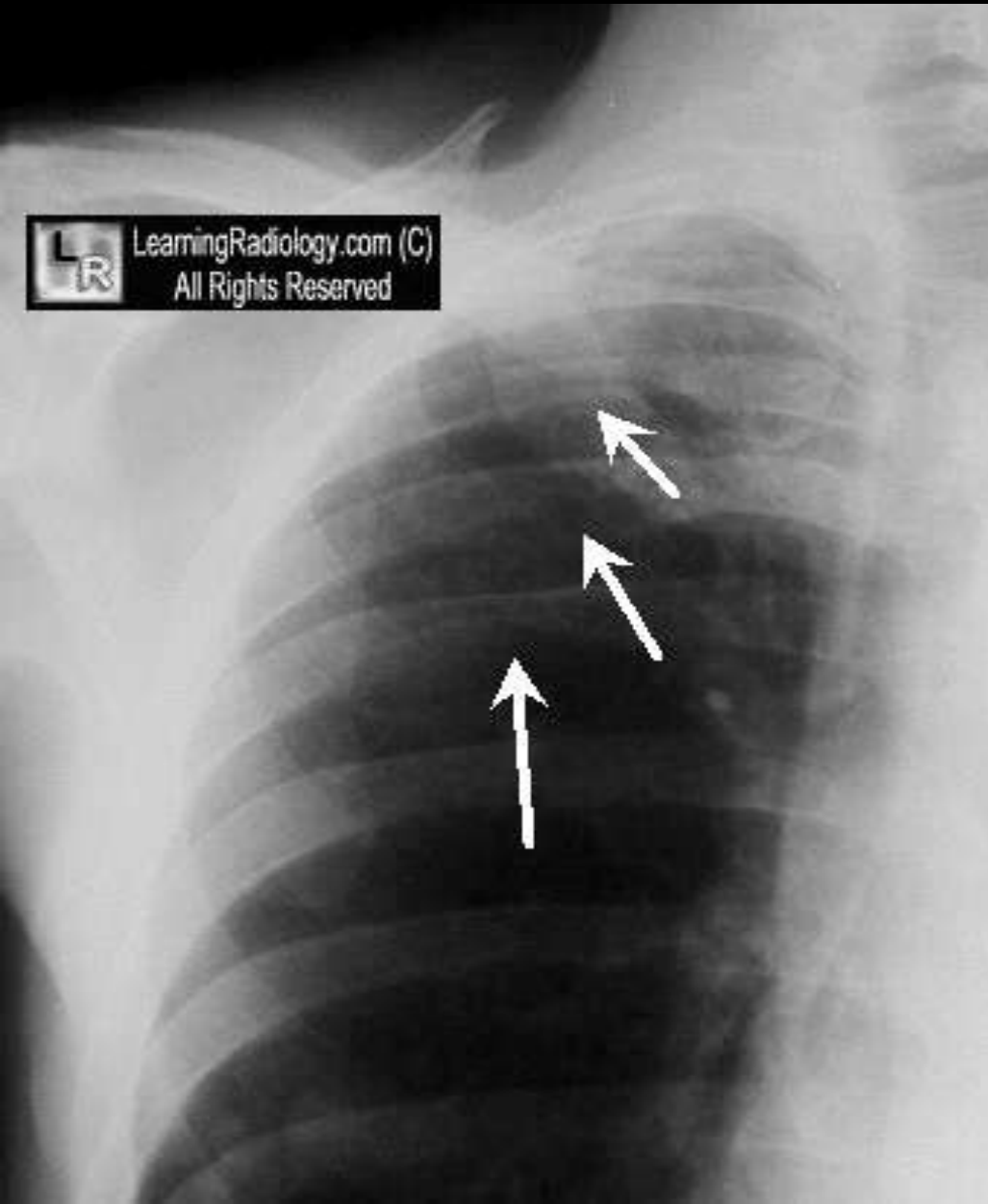
- the process whereby two substances of the same density which touch each other blur the edges between them

Rachitic Rosary



- 
- Enlarged costochondral junctions of the ribs
 - In rickets
 - Resembling a string of rosary beads
 - حبات المسبحة

Ribbon Ribs

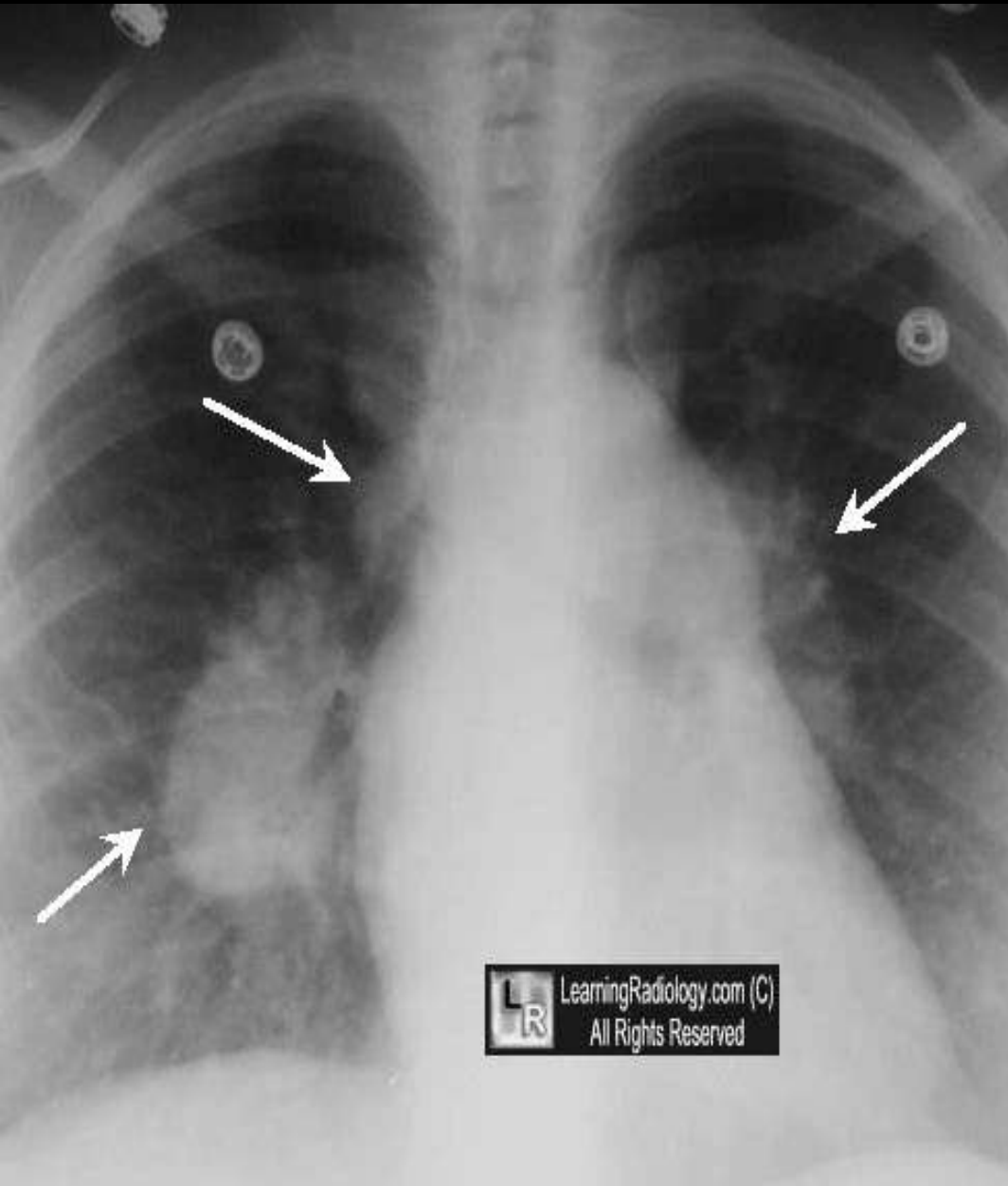


- *thinned and attenuated* appearance of ribs
- usually seen with *neurofibromatosis*

Pawnbroker مقرض المال برهن

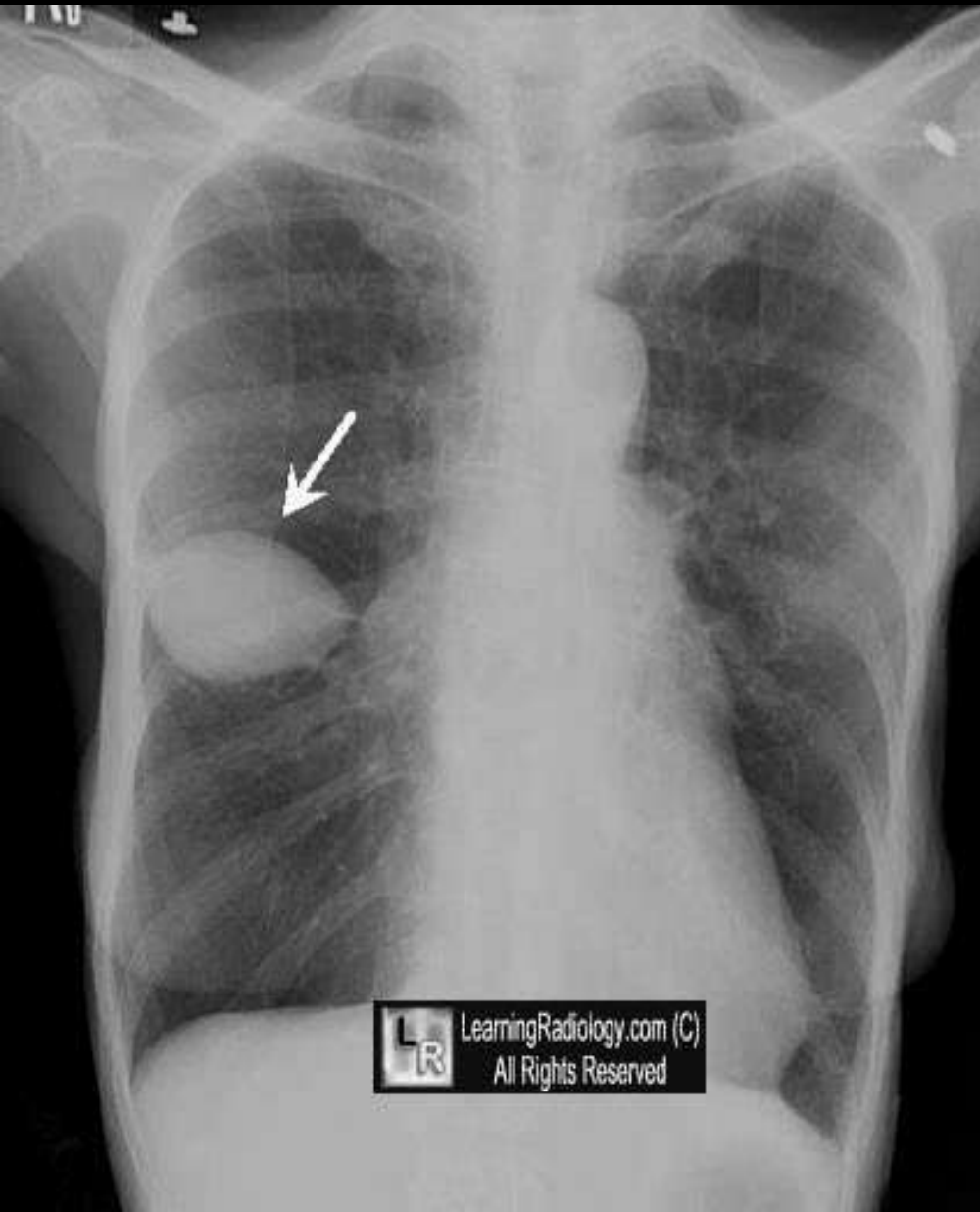


Pawnbroker's Sign



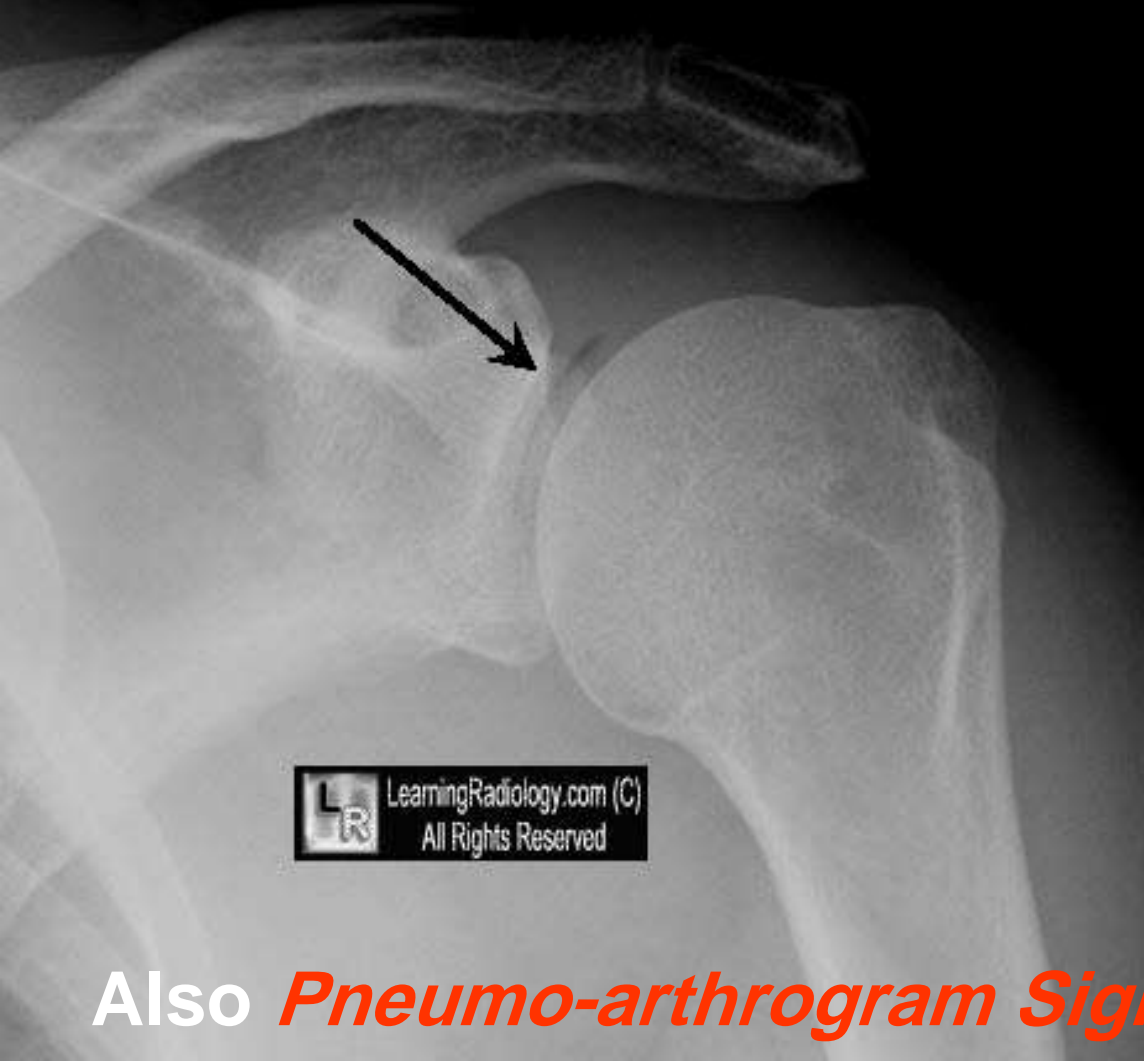
- bilateral hilar and right paratracheal adenopathy
- seen in sarcoid
- resembling 3 hanging balls of *old Pawnbroker's Shops*

Vanishing Tumor Or Psudotumor



- Fluid in a fissure,
- usually minor,
- mostly seen in CHF.

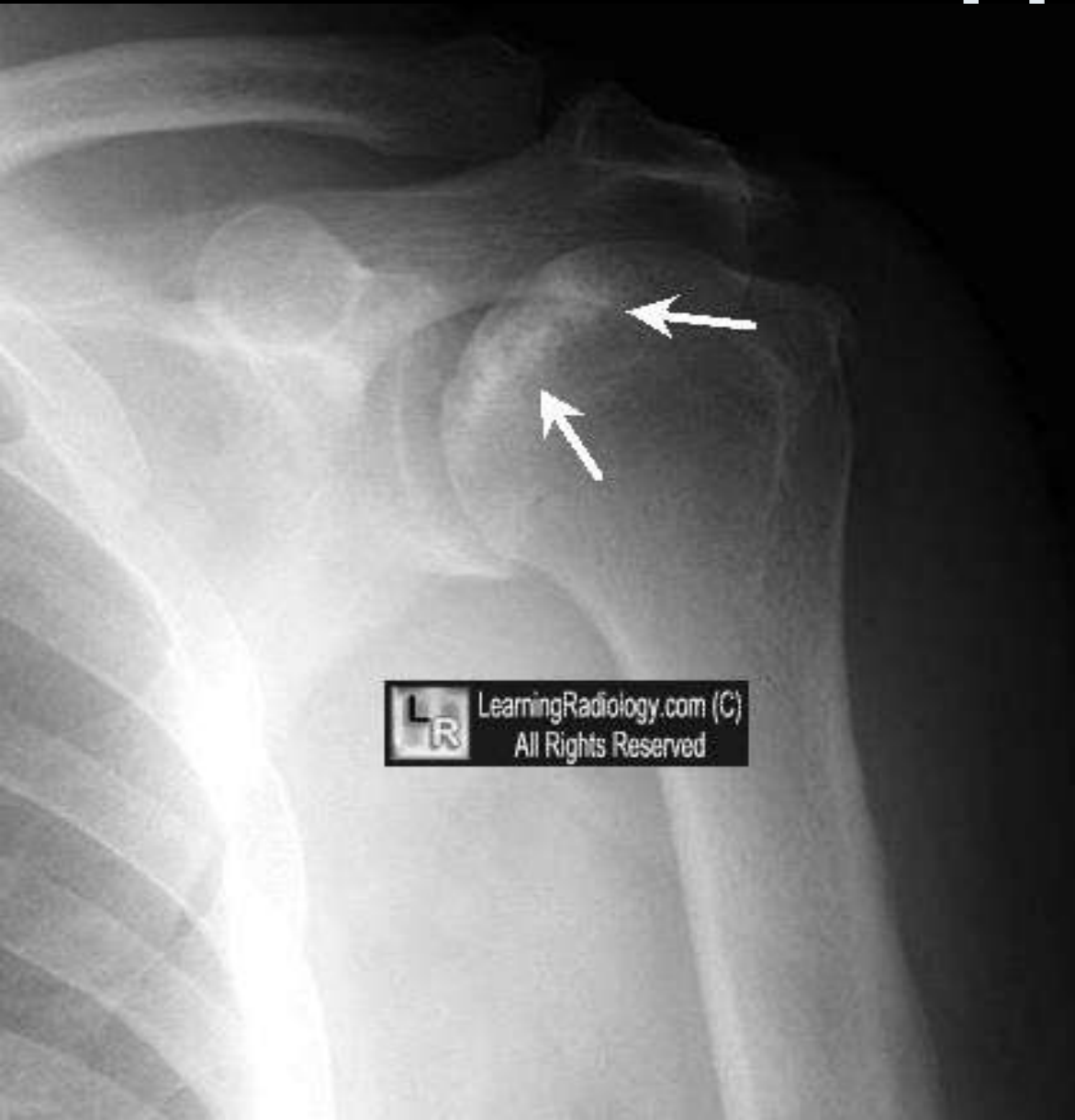
Vacuum Joint Sign



- normal appearance
- gasses (nitrogen) that come out of solution in a large joint
- from traction.

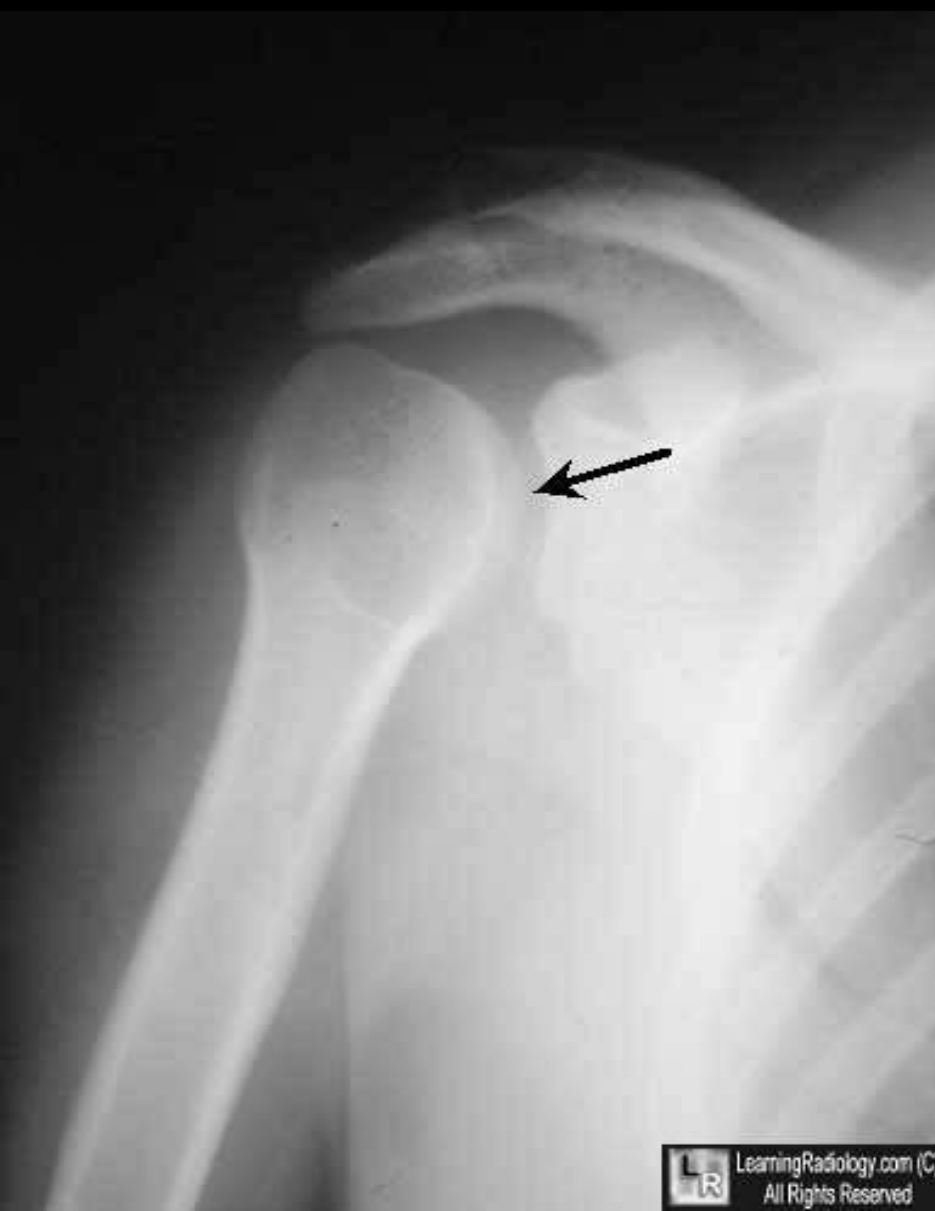Also *Pneumo-arthrogram Sign*

Snow-capping



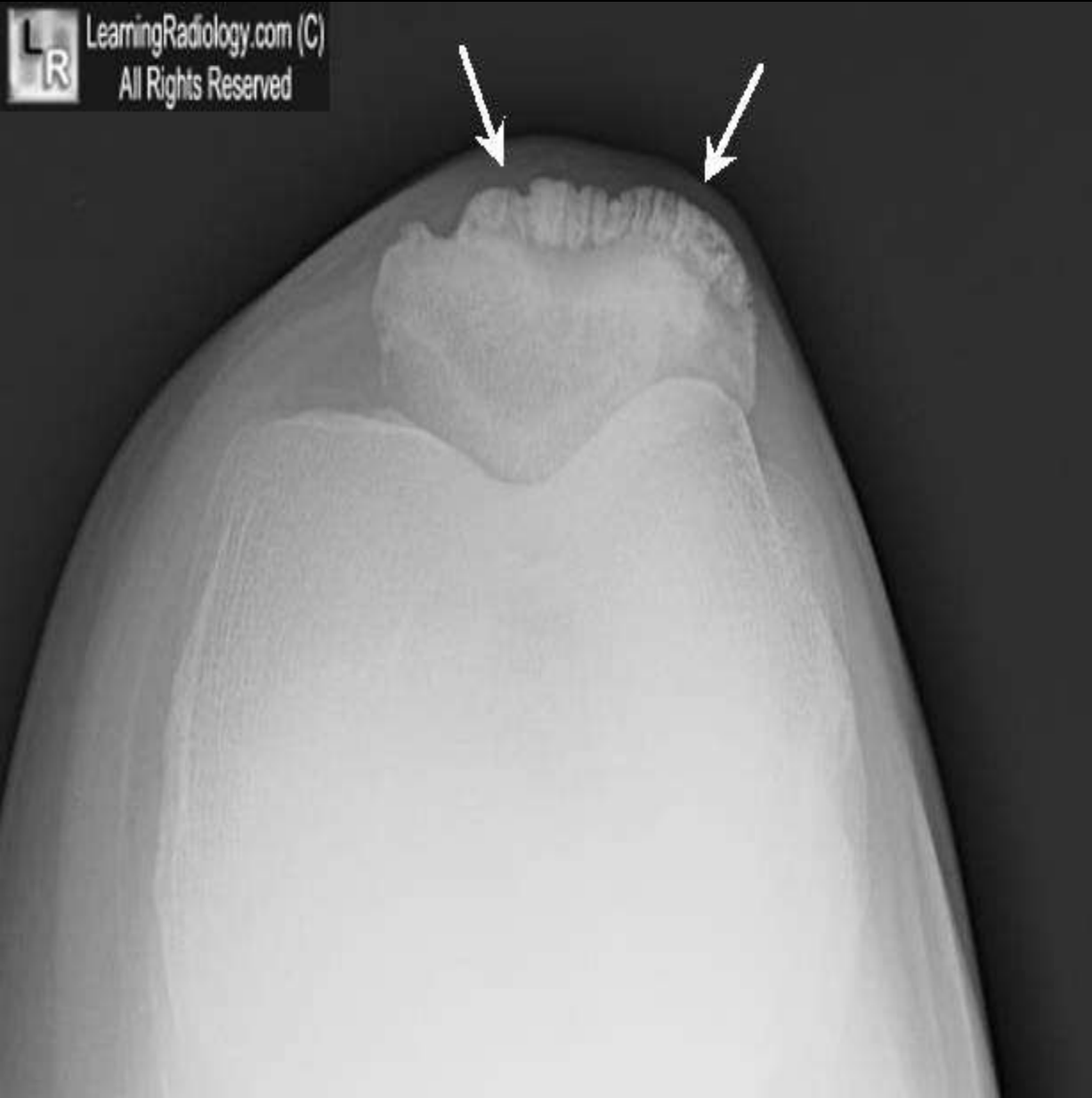- Dense appearance of humeral head
- In avascular necrosis
- Resemble snow on mountain top

Trough Sign

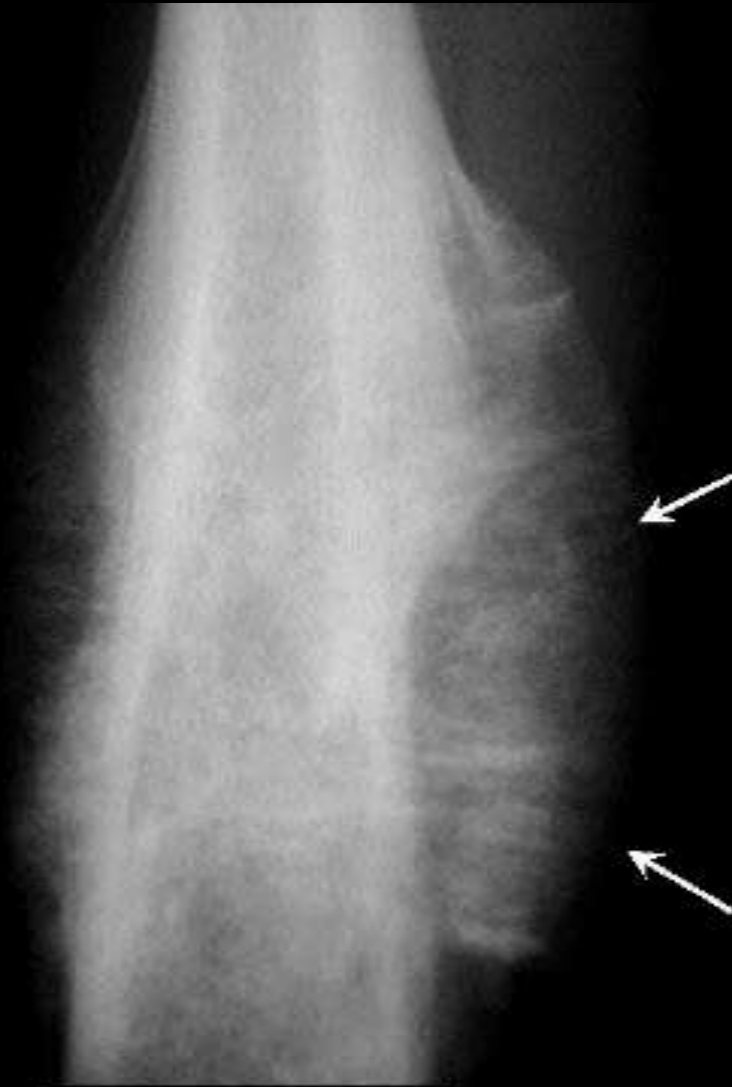

- linear fracture of the anterior and medial portion of the humeral head
- from a posterior shoulder dislocation
- Trough= حوض – قناة - غور

Tooth Sign



Sunburst Periosteal Reaction



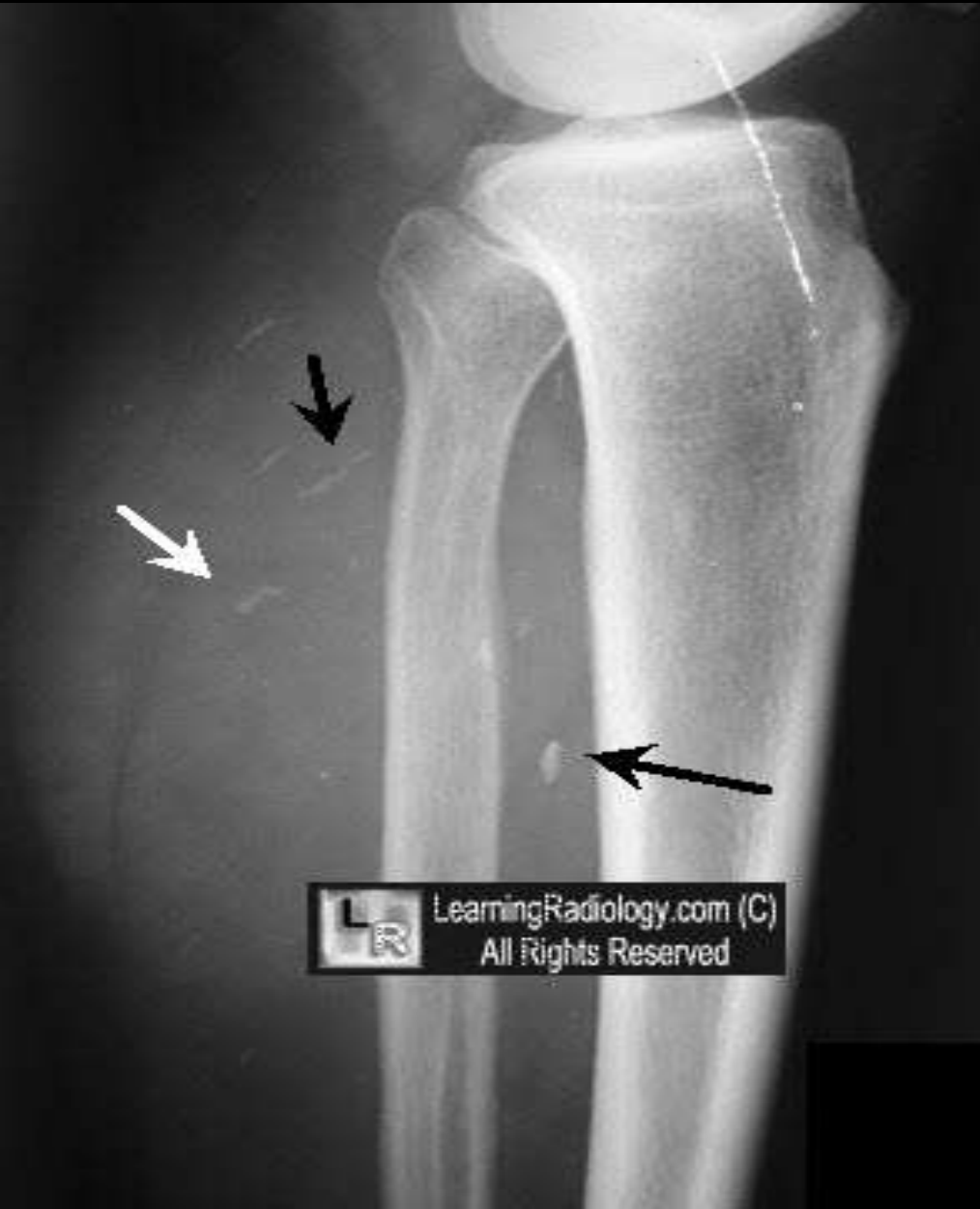LearningRadiology.com (C)
All Rights Reserved

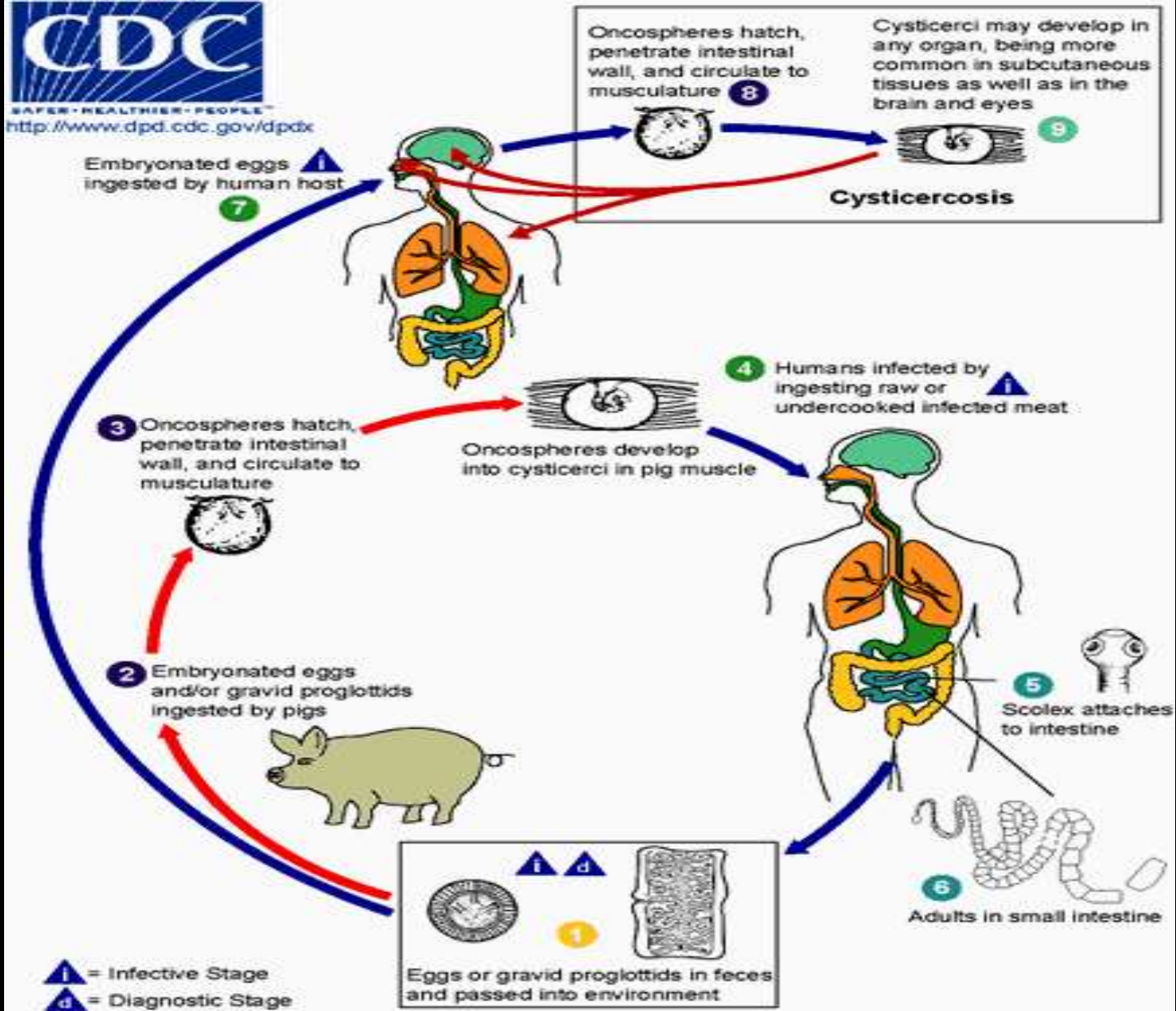
- highly aggressive spiculated reaction
- indicating a malignancy such as osteosarcoma



Rice Grain Calcifications

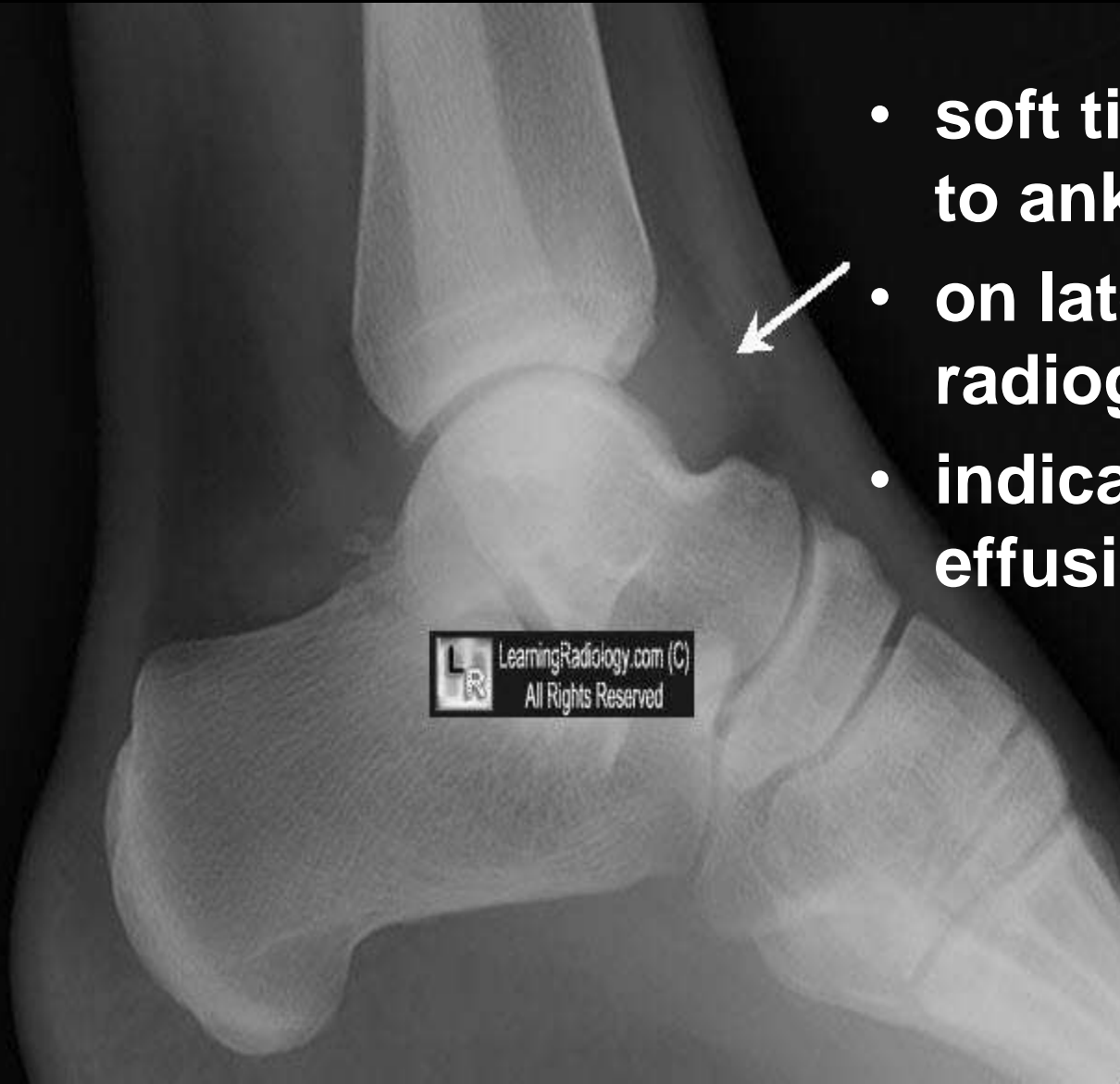
- elongated oval-shaped, soft tissue calcifications the size of rice grains
- seen in cysticercosis





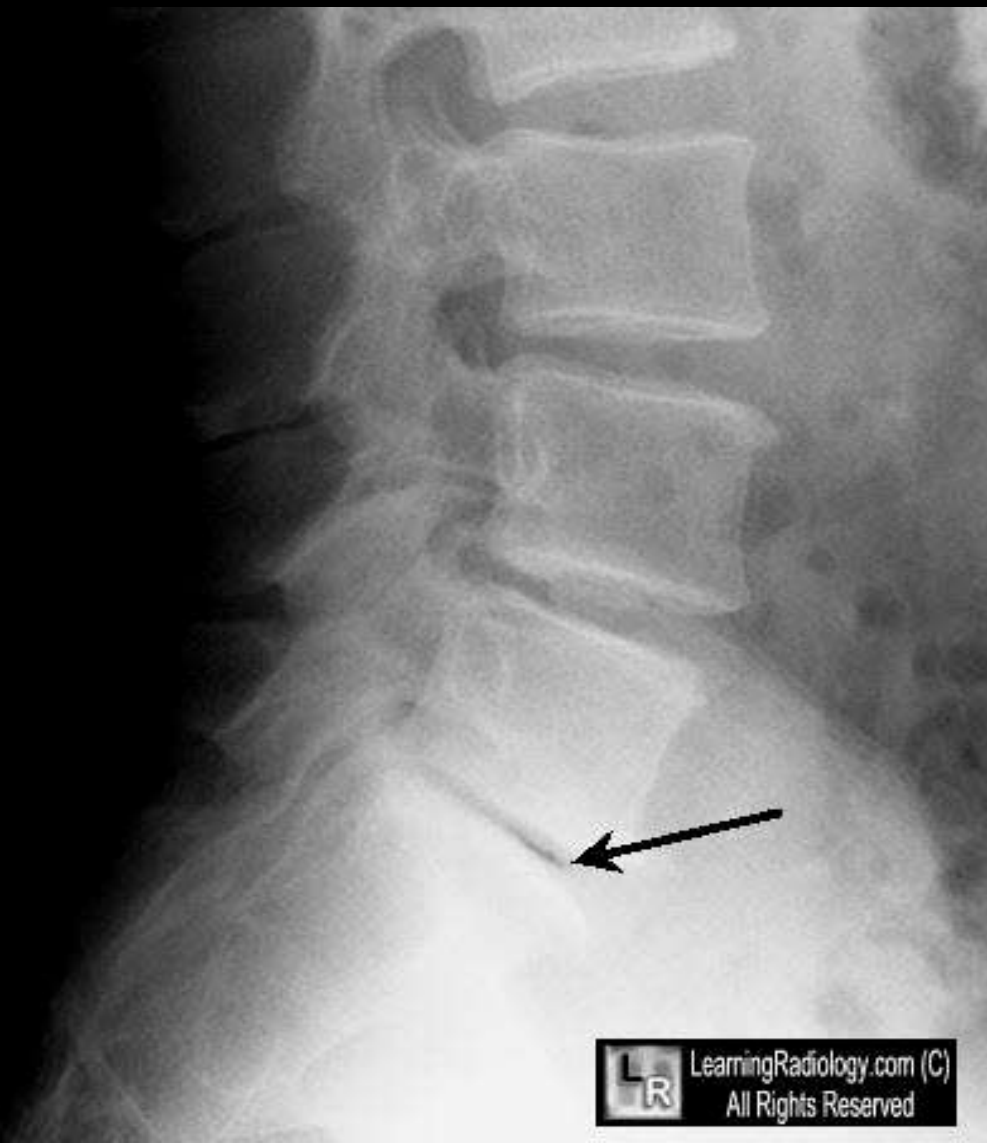
of pork **Cysticercosis** refers to tissue infection after exposure to eggs of '*Taenia solium* tapeworm

(ankle)Teardrop Sign



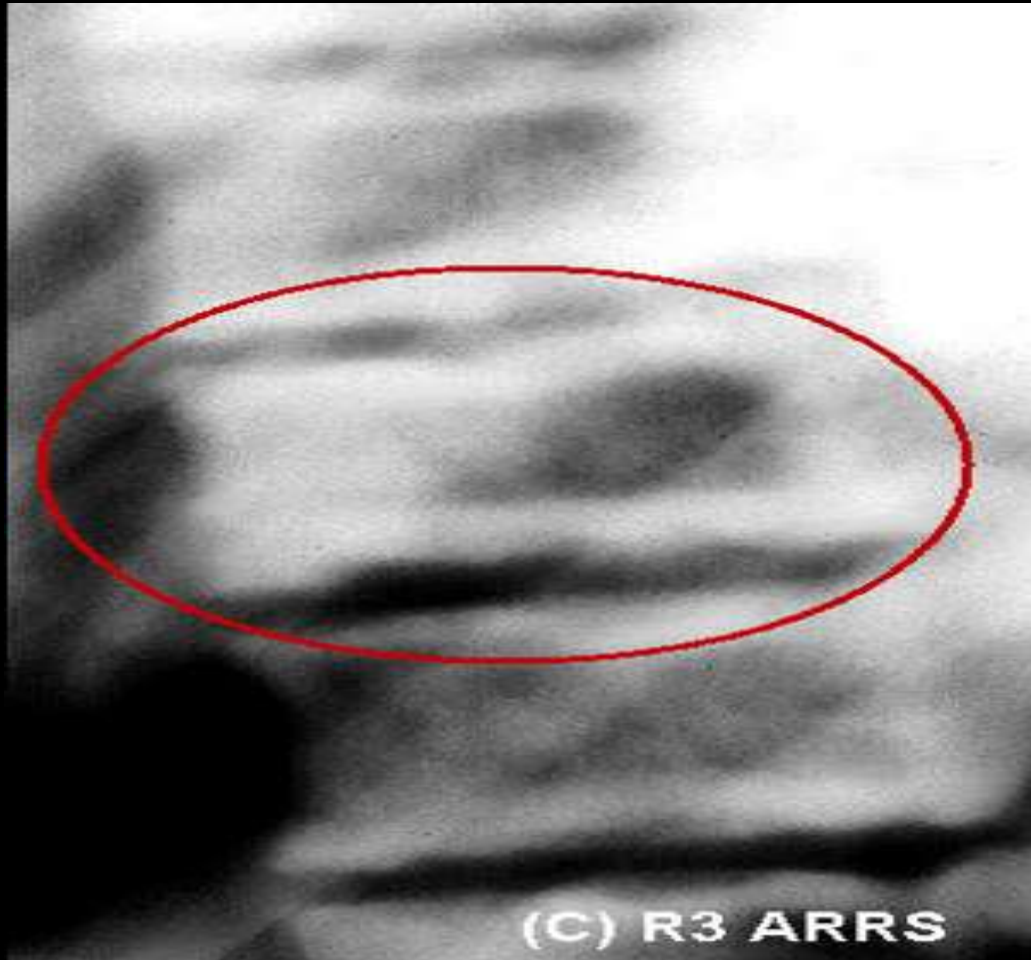- soft tissue anterior to ankle joint
- on lateral radiograph
- indicating a joint effusion

Vacuum Disk Sign

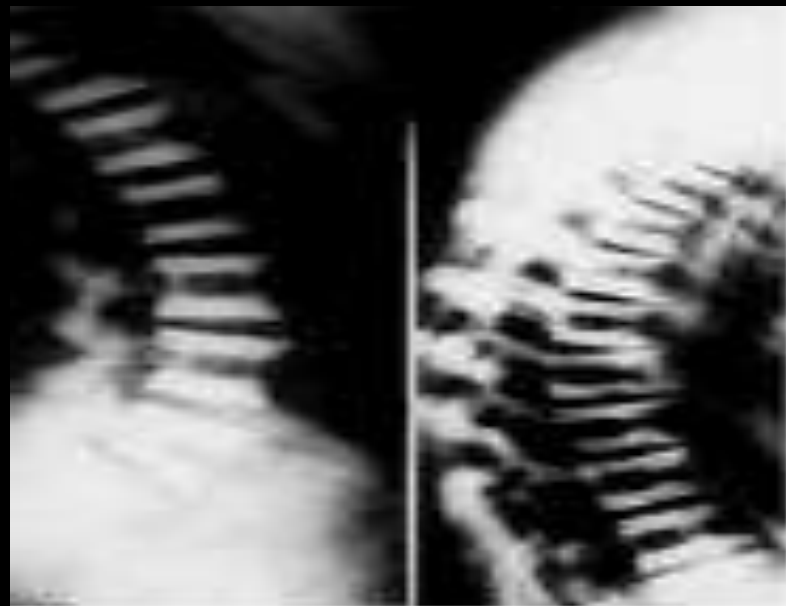

- abnormal gas in the disk
- in degenerative disk disease;
- *vacuum joint sign is normal*

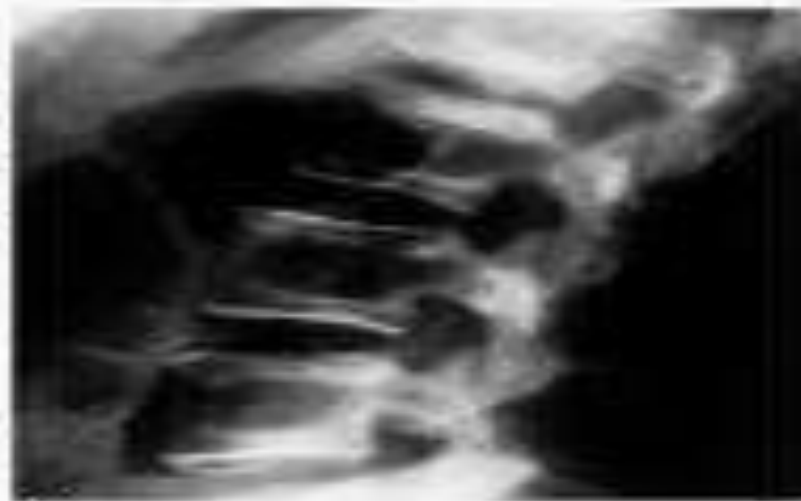Sandwich Vertebra



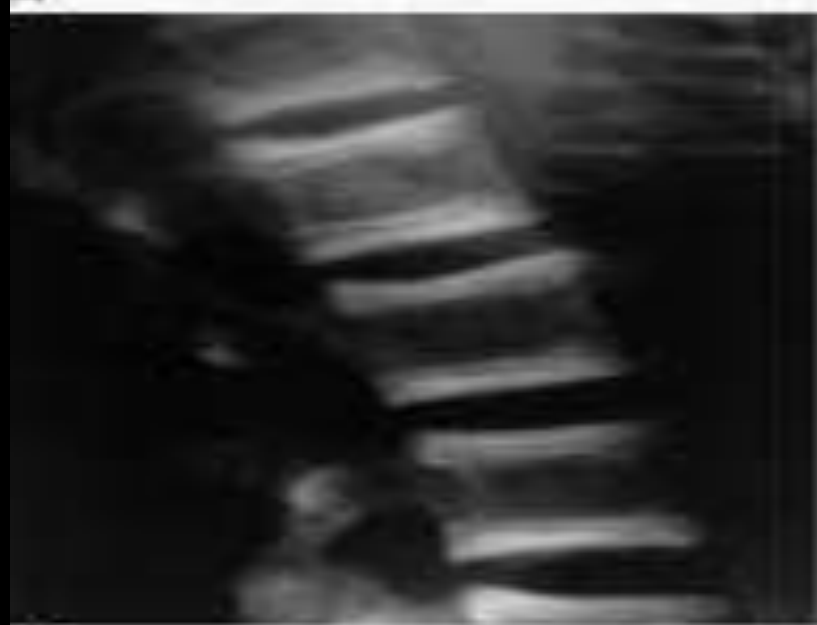
- appearance of vertebra in osteopetrosis
- due to increased density of endplates



A

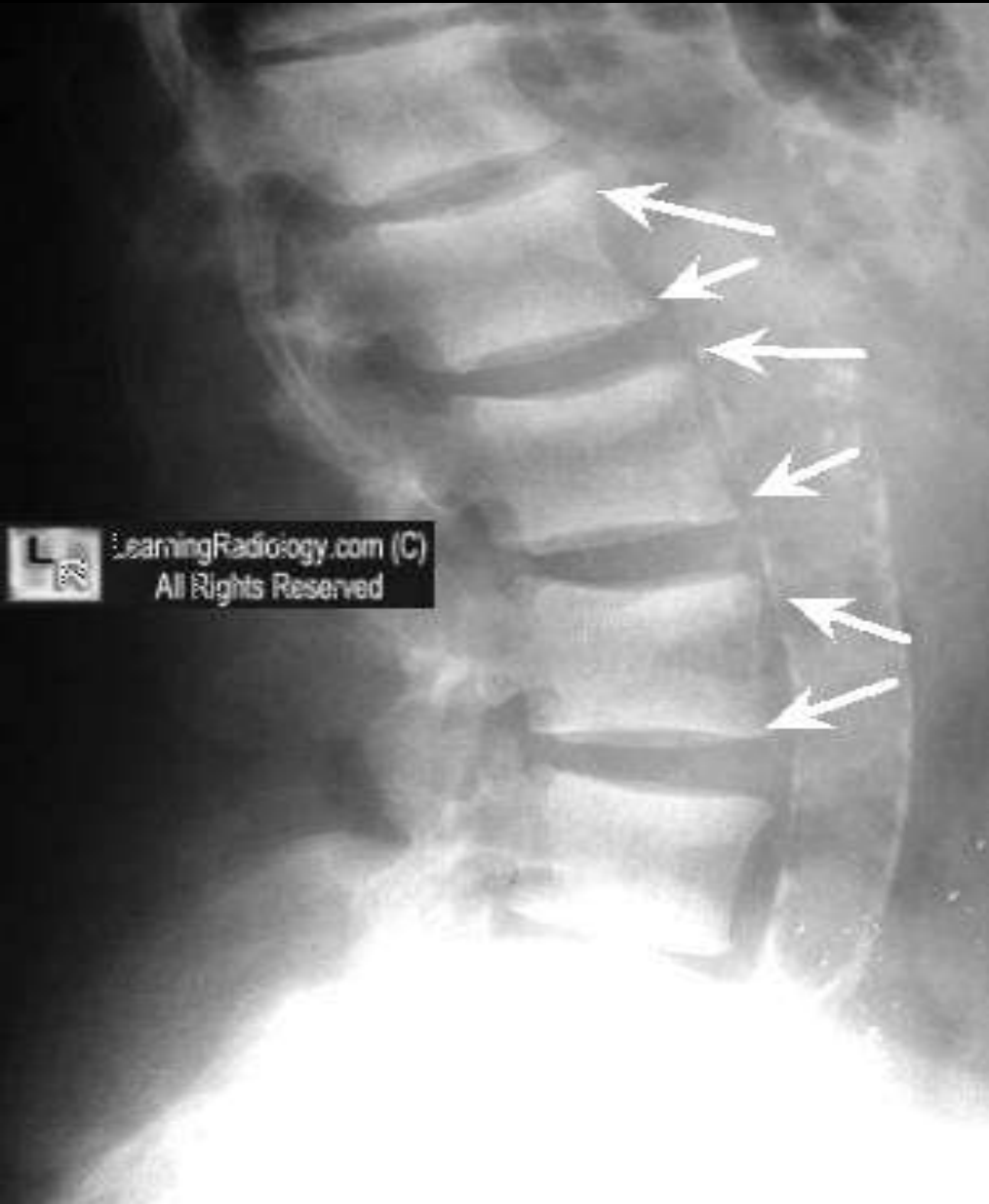

B



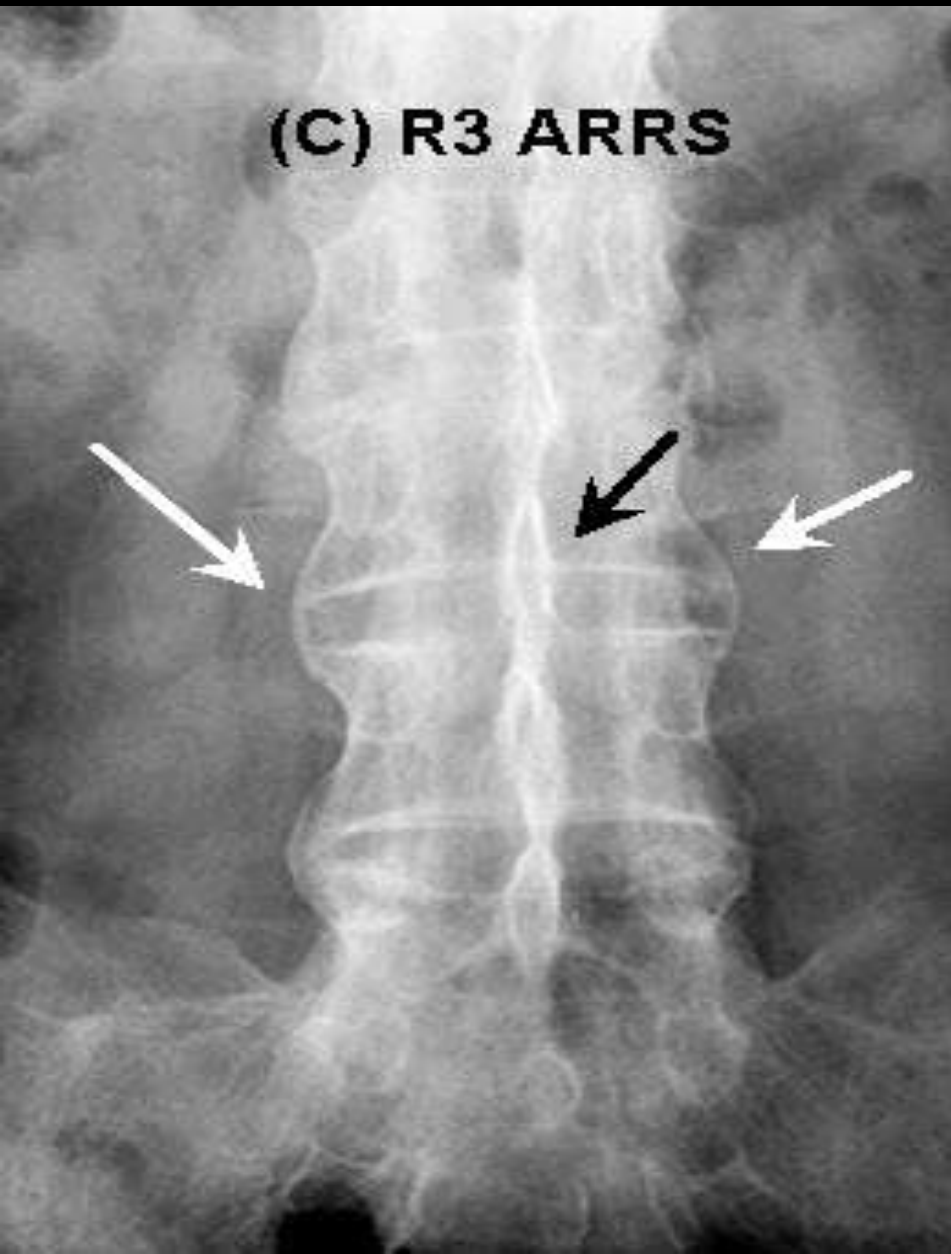
C

Rugger Jersey Spine



- **sclerotic superior and inferior endplates of vertebrae**
- **from :**
 - **secondary hyperparathyroidism**
 - **renal disease**

Trolley Track Sign



- combination of :
bamboo spine +
ossification of the
interspinous ligaments
- in ankylosing
spondylitis

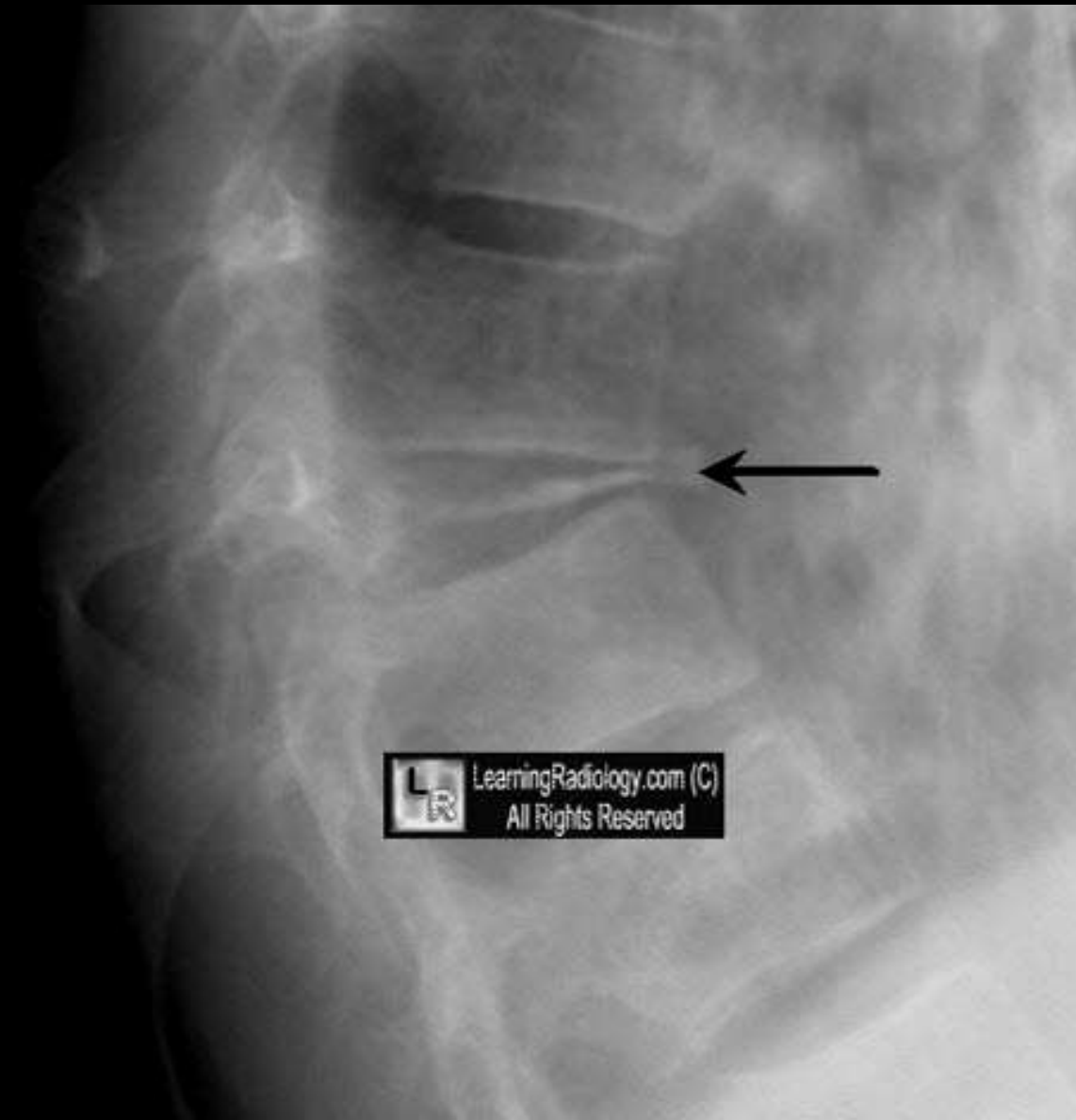Pedicle Sign

- destruction of the vertebral pedicle,
- seen more with *lytic metastatic* disease than multiple myeloma



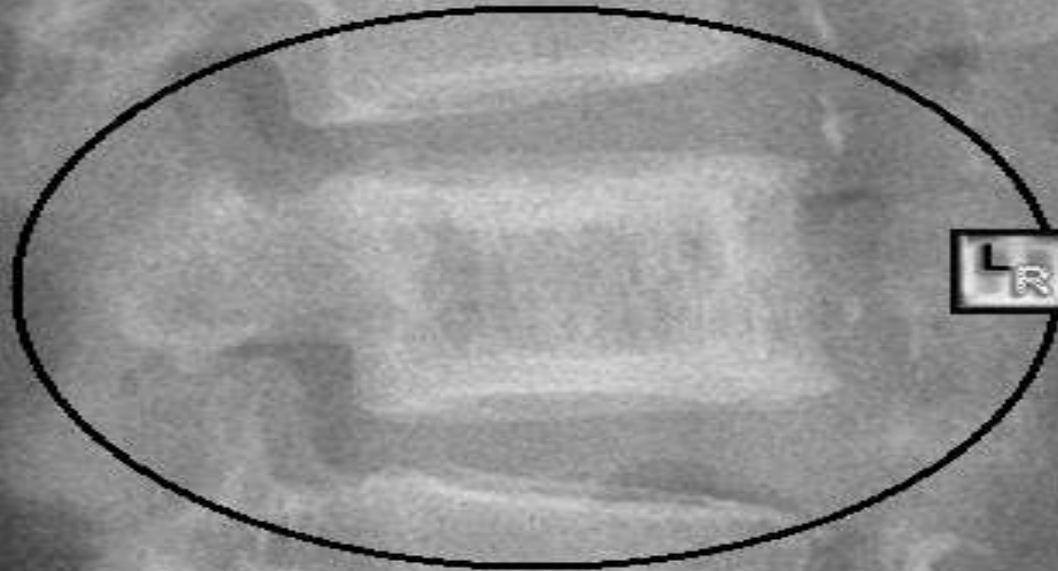
LearningRadio.org (C)
All Rights Reserved

Pancake Vertebra



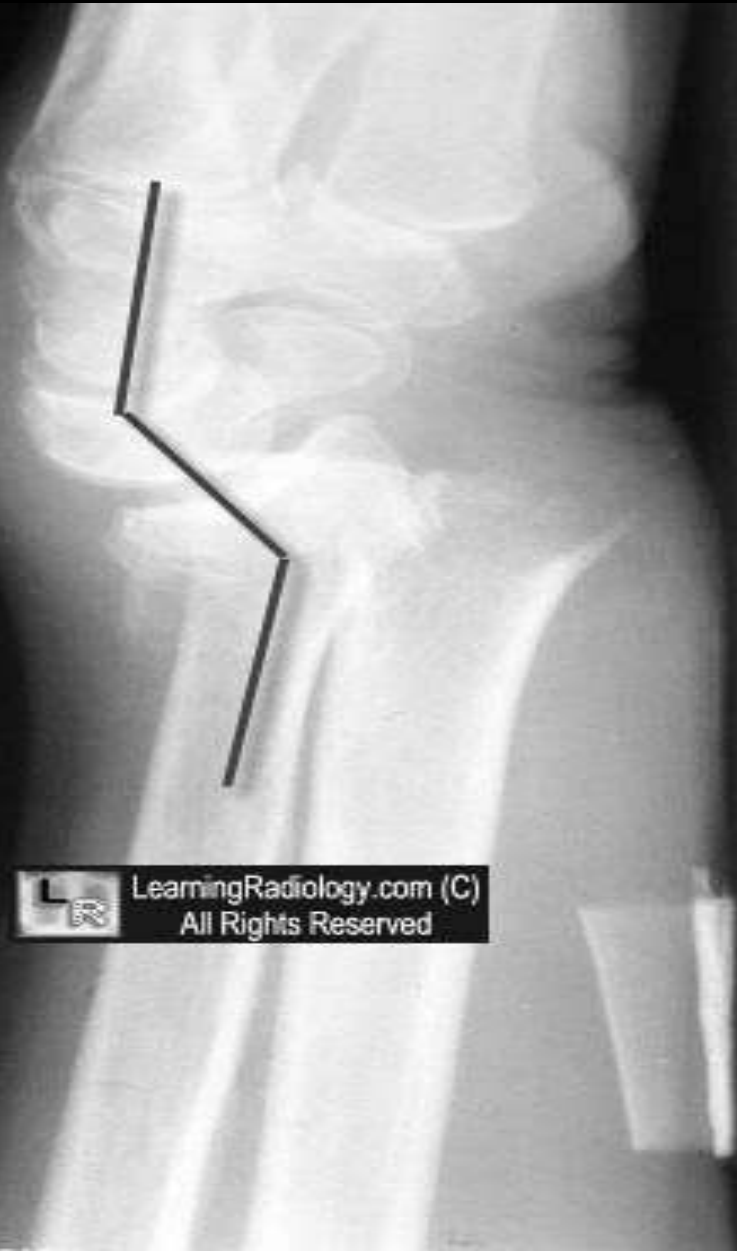- (vertebra plana)
- flattening of a vertebral body
- from a compression fracture as in eosinophilic granuloma

Picture Framing

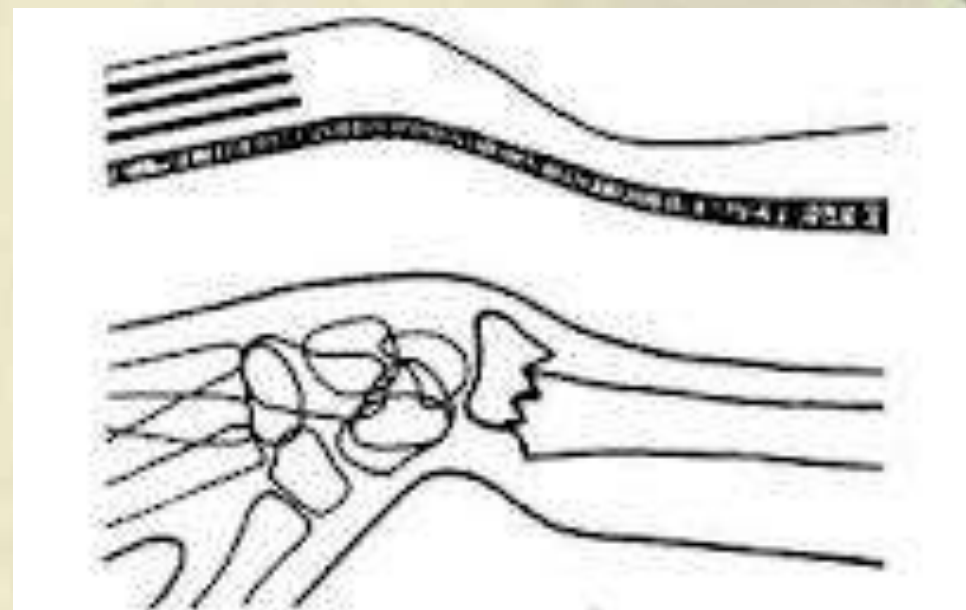
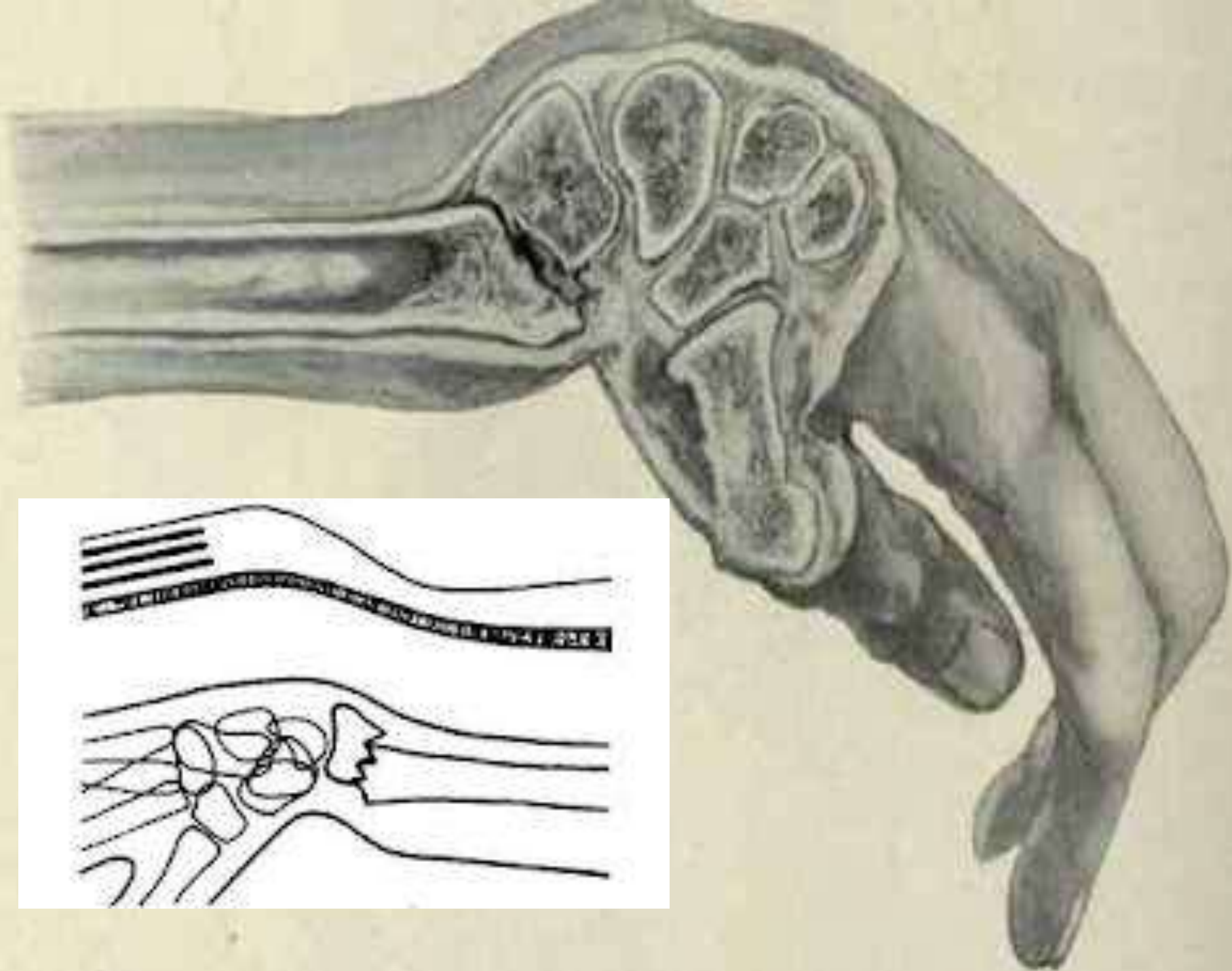


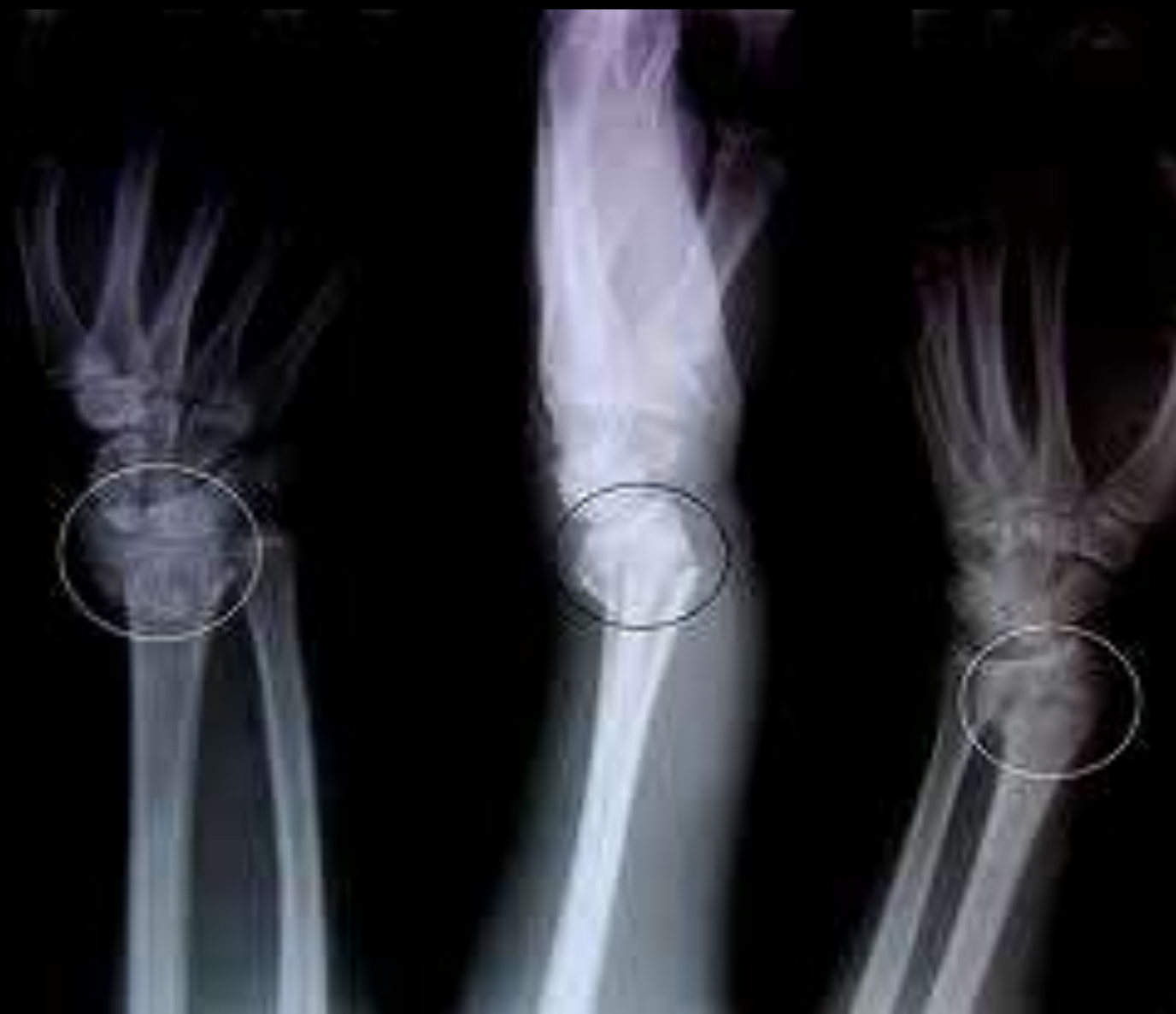- Thickened cortex of a vertebral body
- with *Paget's disease*
- Resembling a picture frame

Silver Fork Deformity

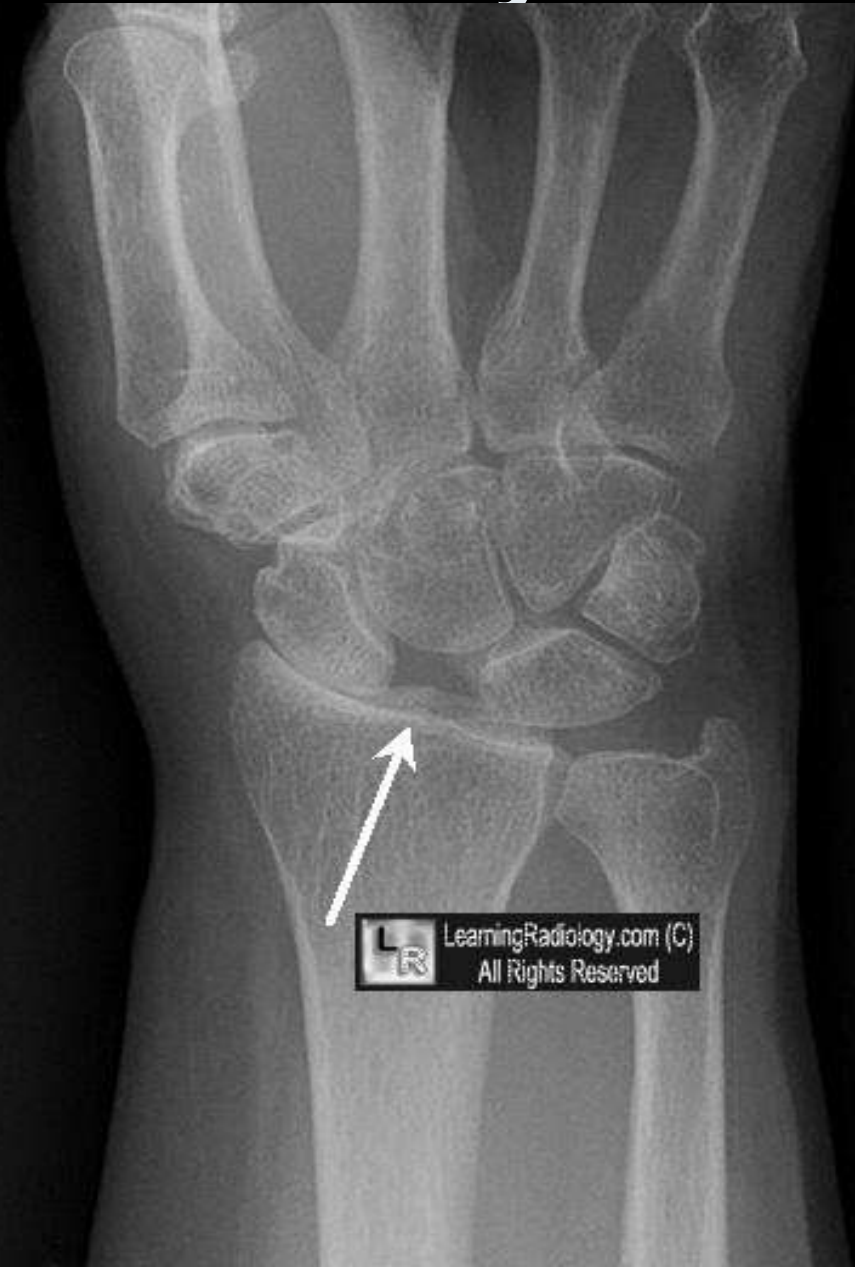

- appearance of acutely dorsally angulated wrist
- from distal radius fracture
- seen in Colles fx

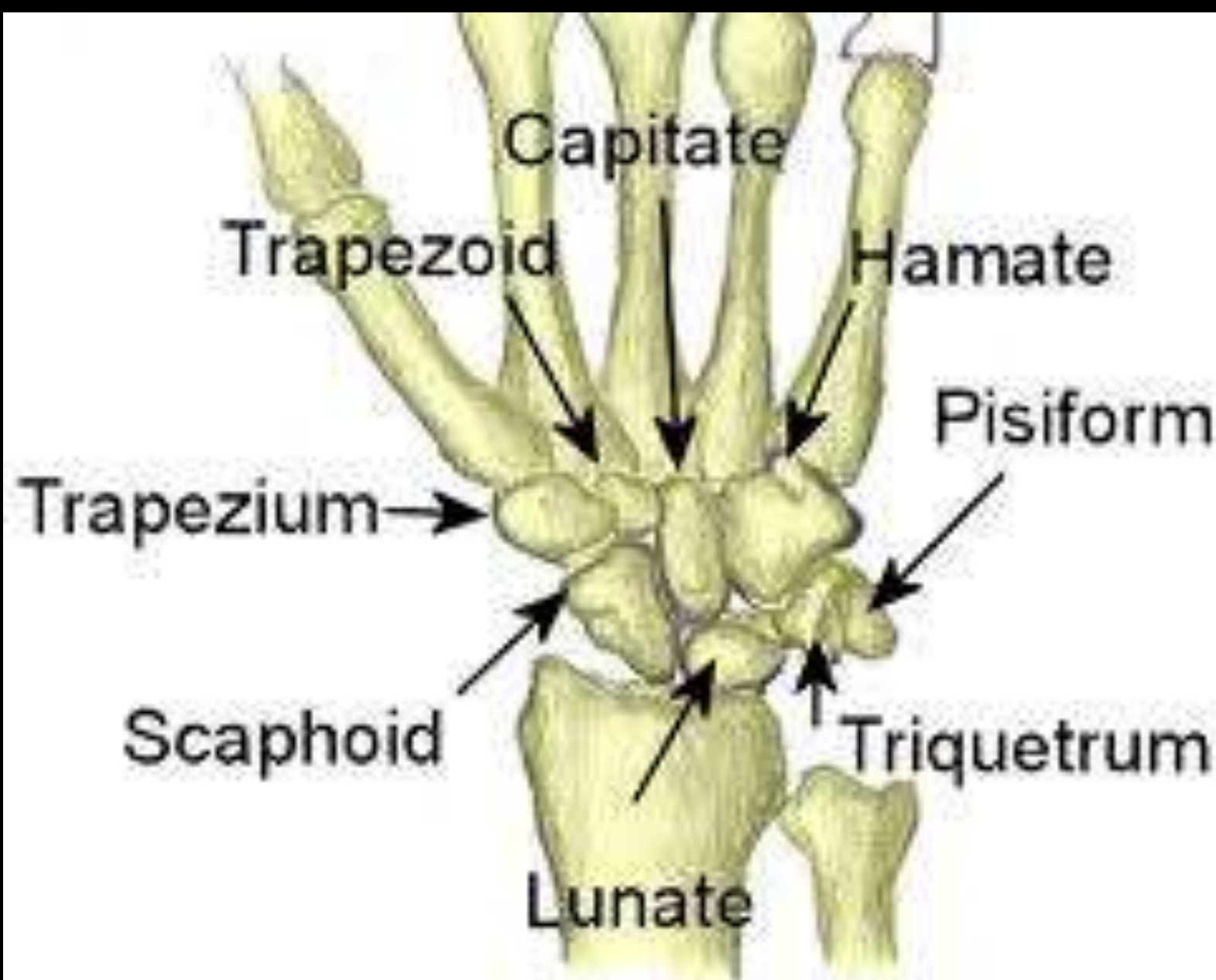


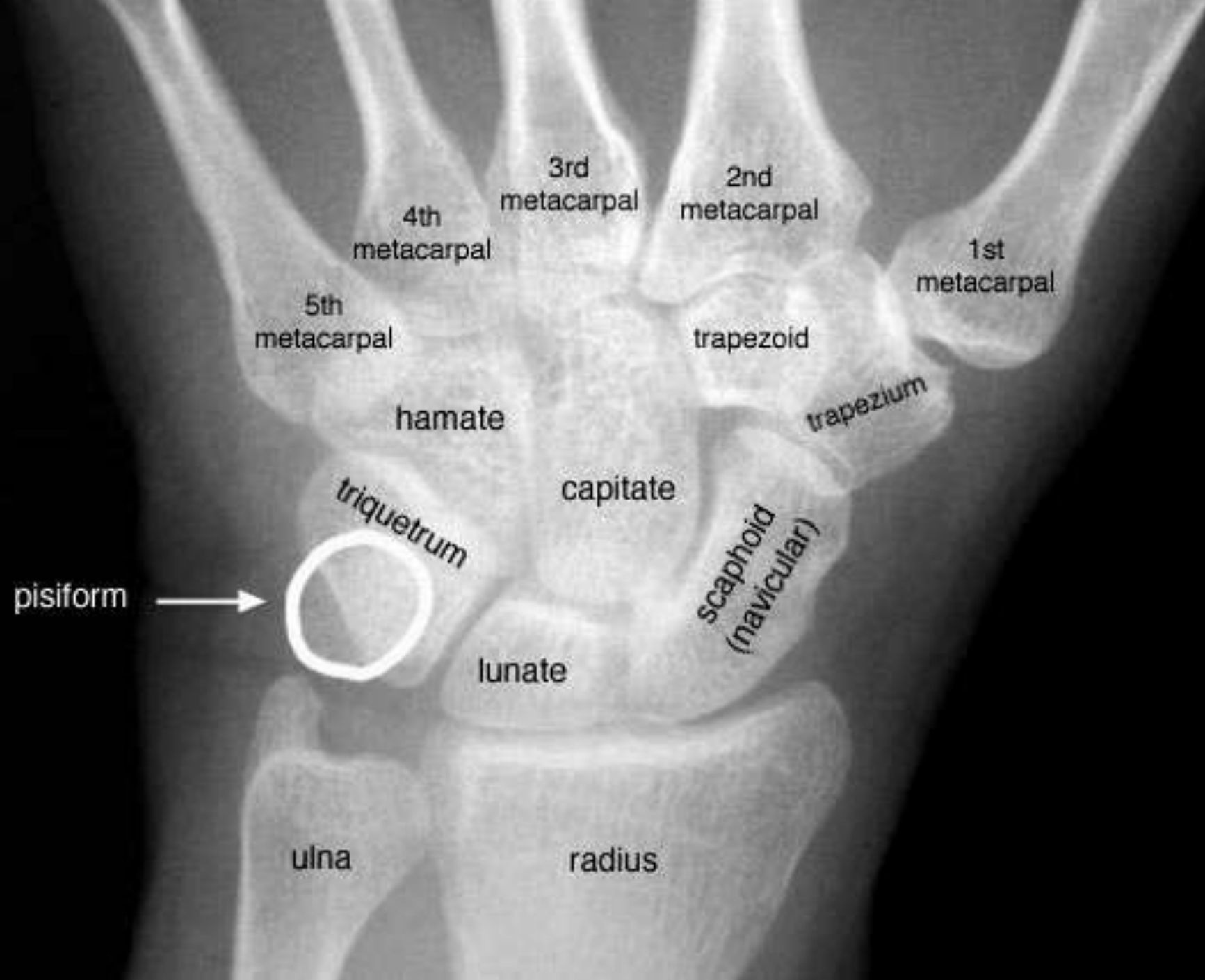

Terry Thomas Sign

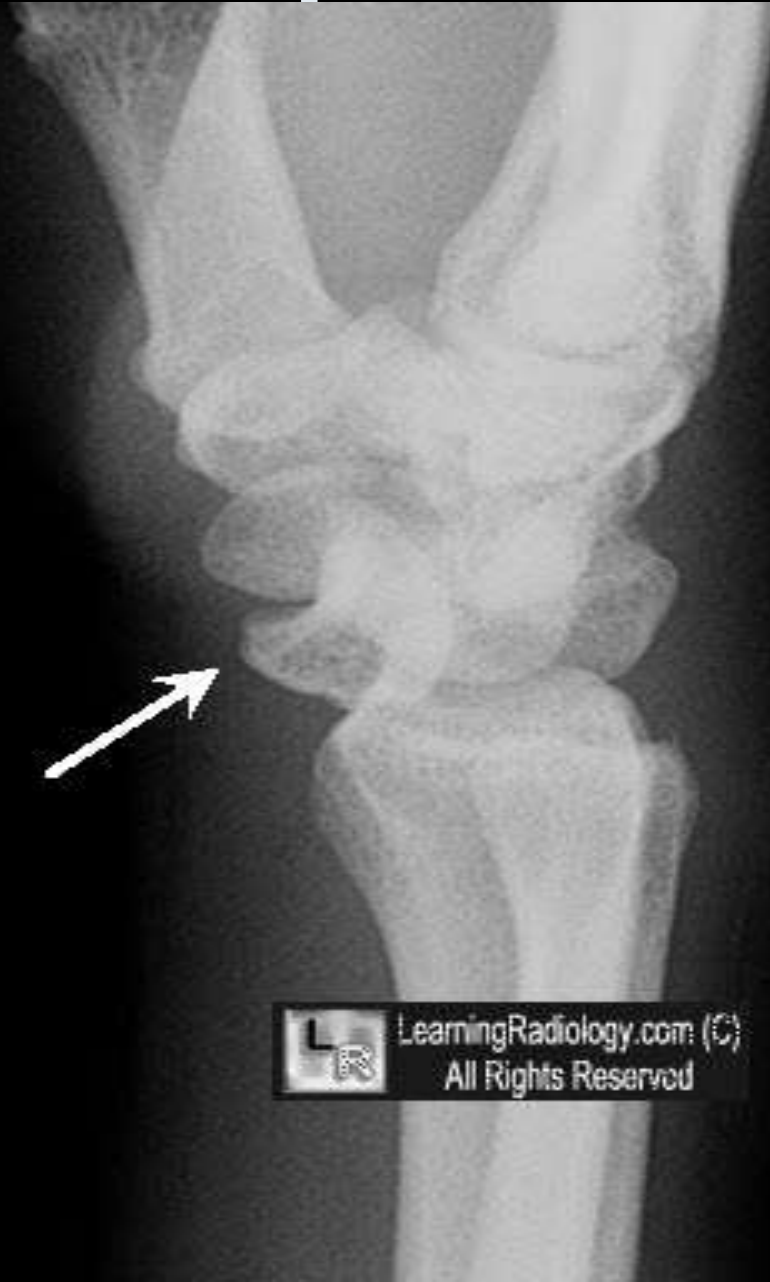

- widening of distance between the scaphoid and lunate (>3mm)
- on PA view
- from ligament disruption





Spilled Teacup Sign



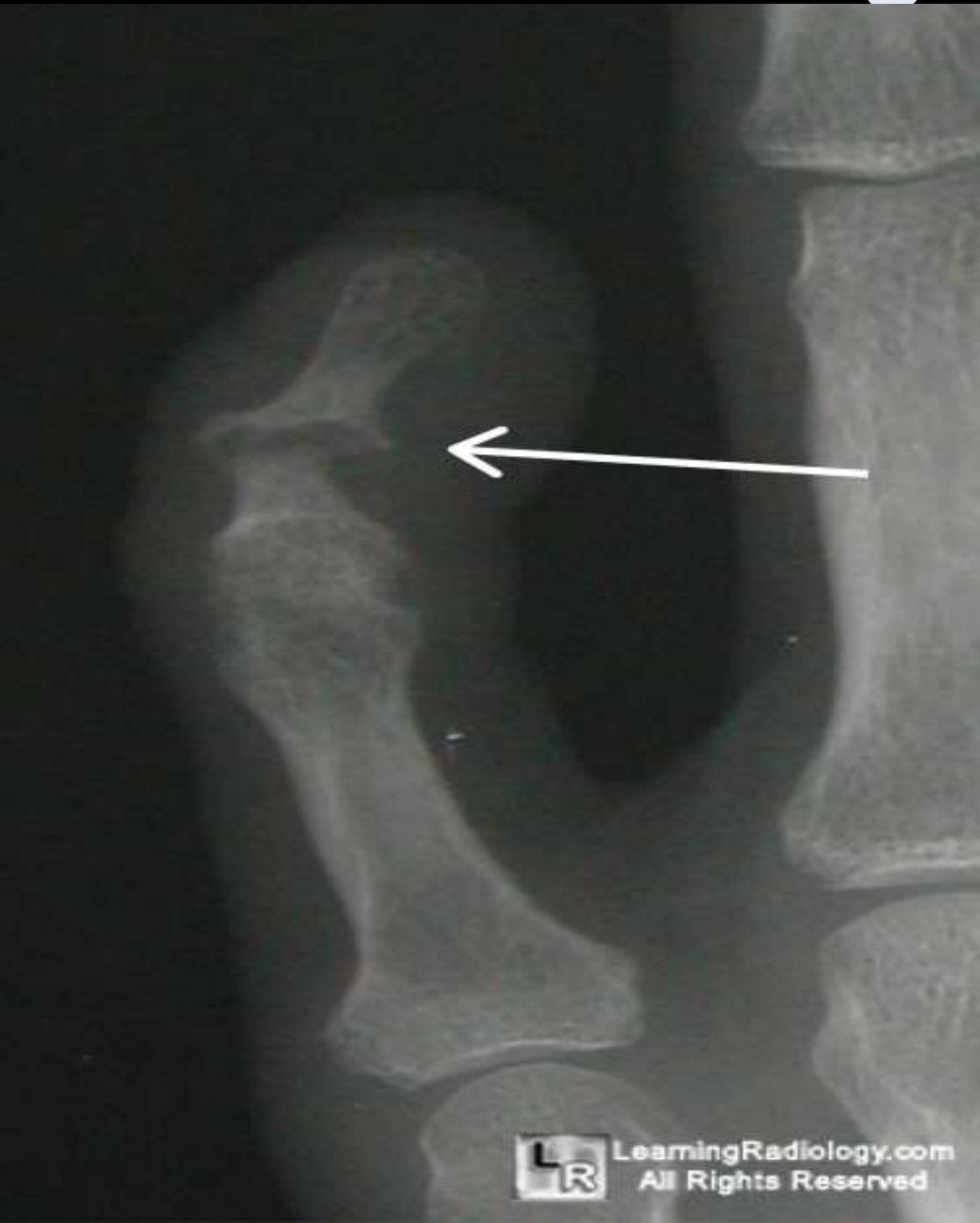- appearance of volar displaced concave surface of lunate
- in a lunate dislocation



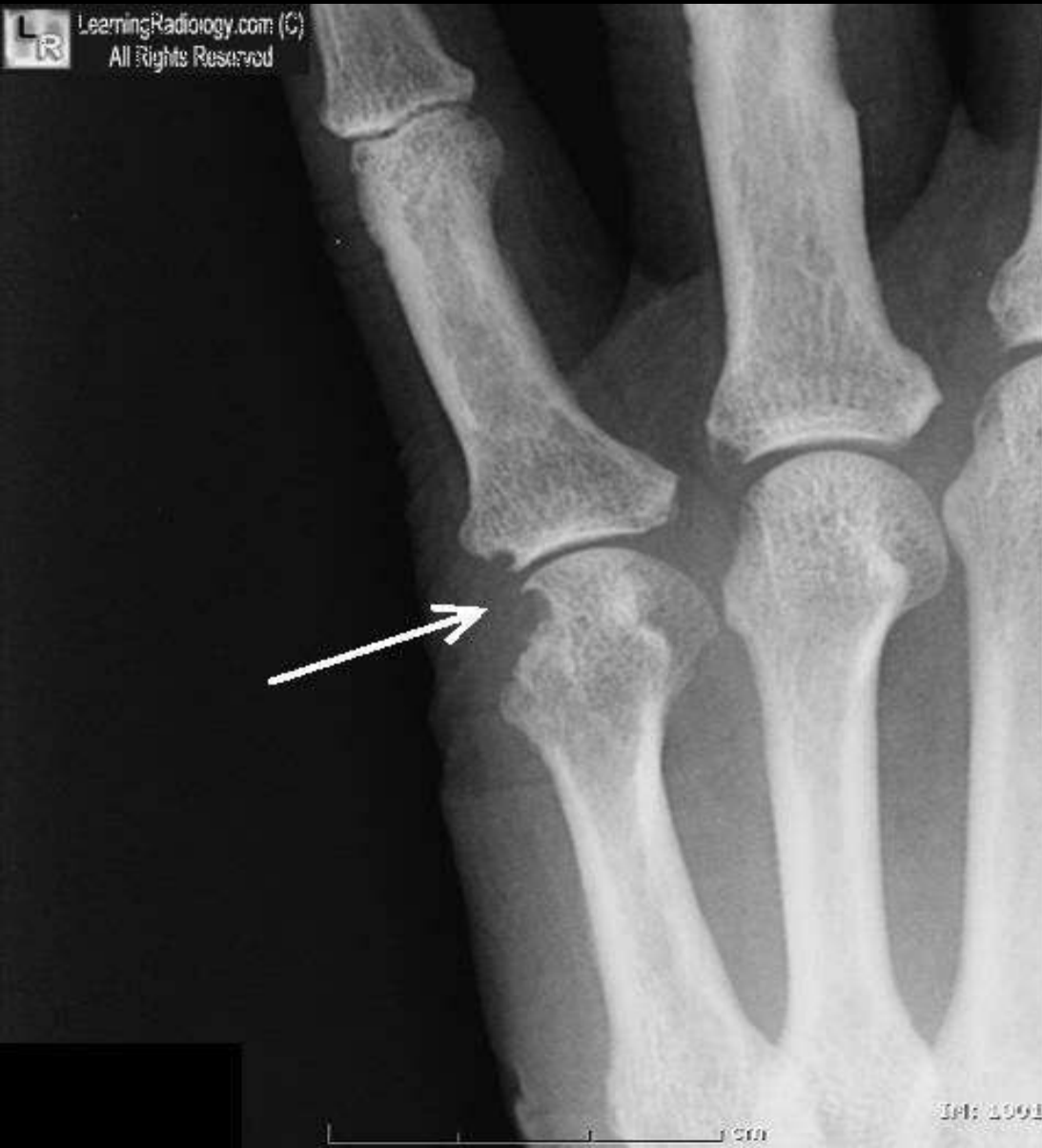LearningRadiology.com (C)
All Rights Reserved

Sausage Digit

- fusiform swelling
- of a single digit
- Resembling a cocktail sausage,
- classically seen in *psoriasis*

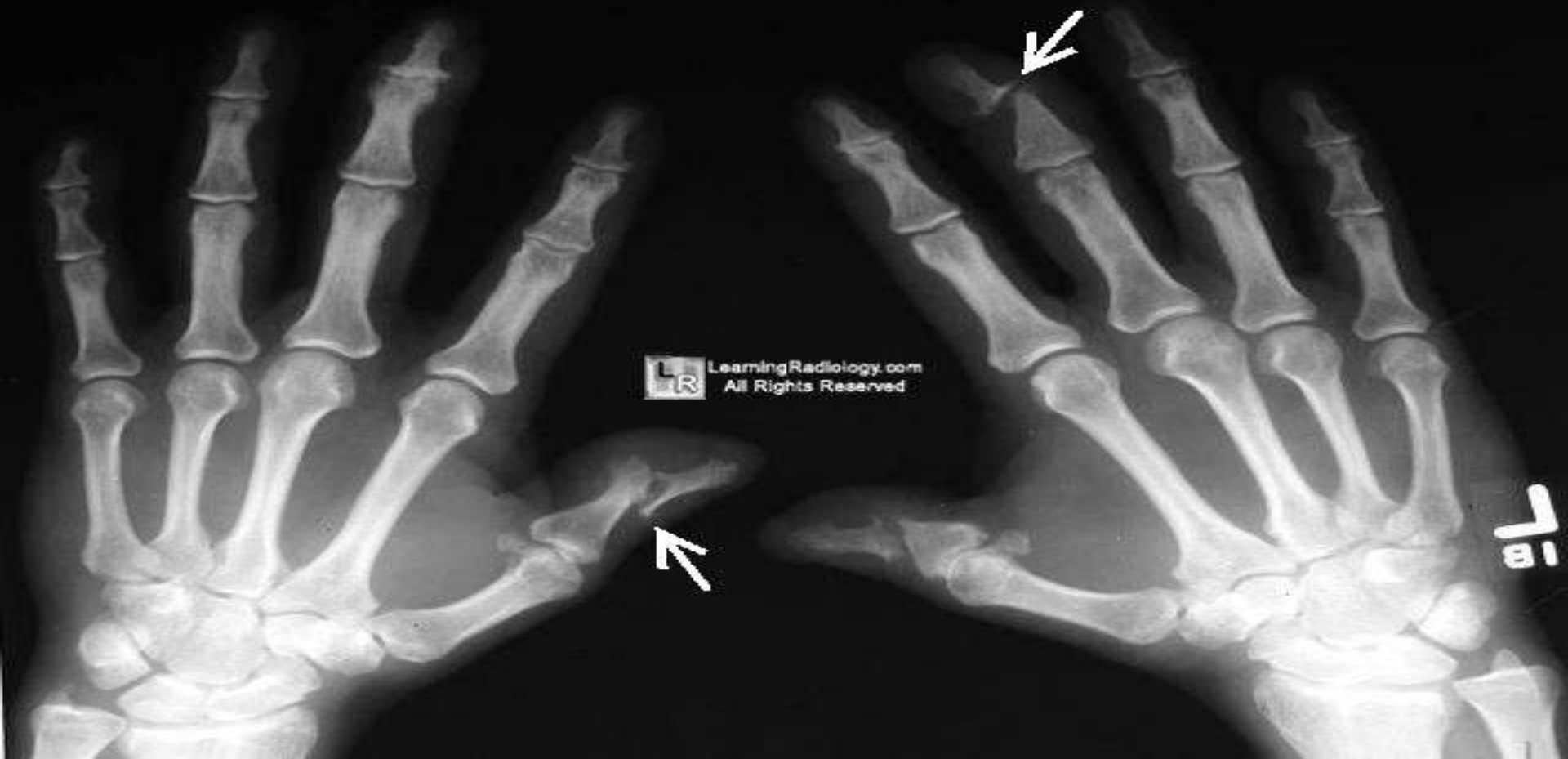

Rat-bite Sign



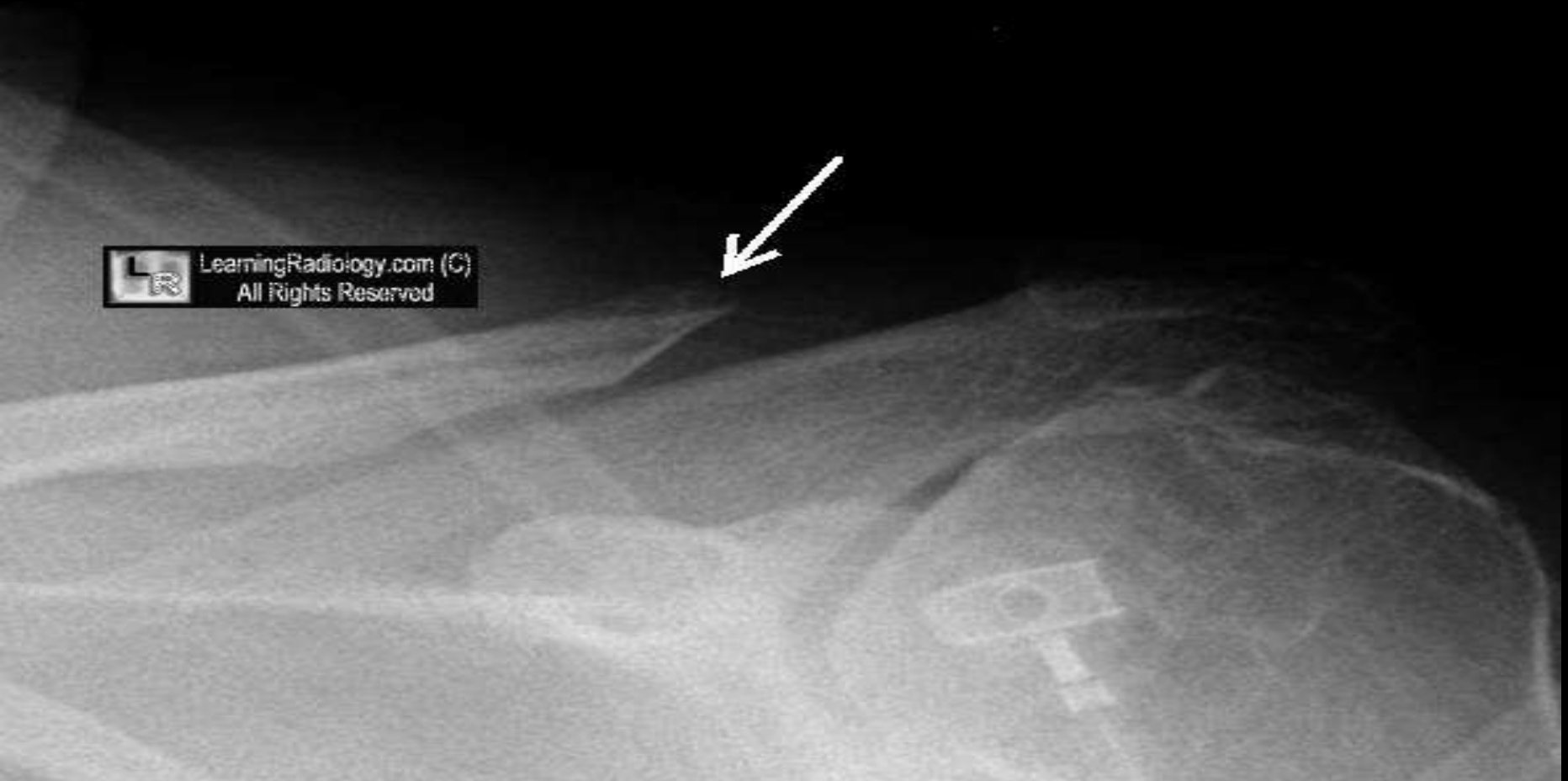- **sharply margined, overhanging bony erosions**
- **usually with gouty arthritis**

Pencil-in-Cup Sign



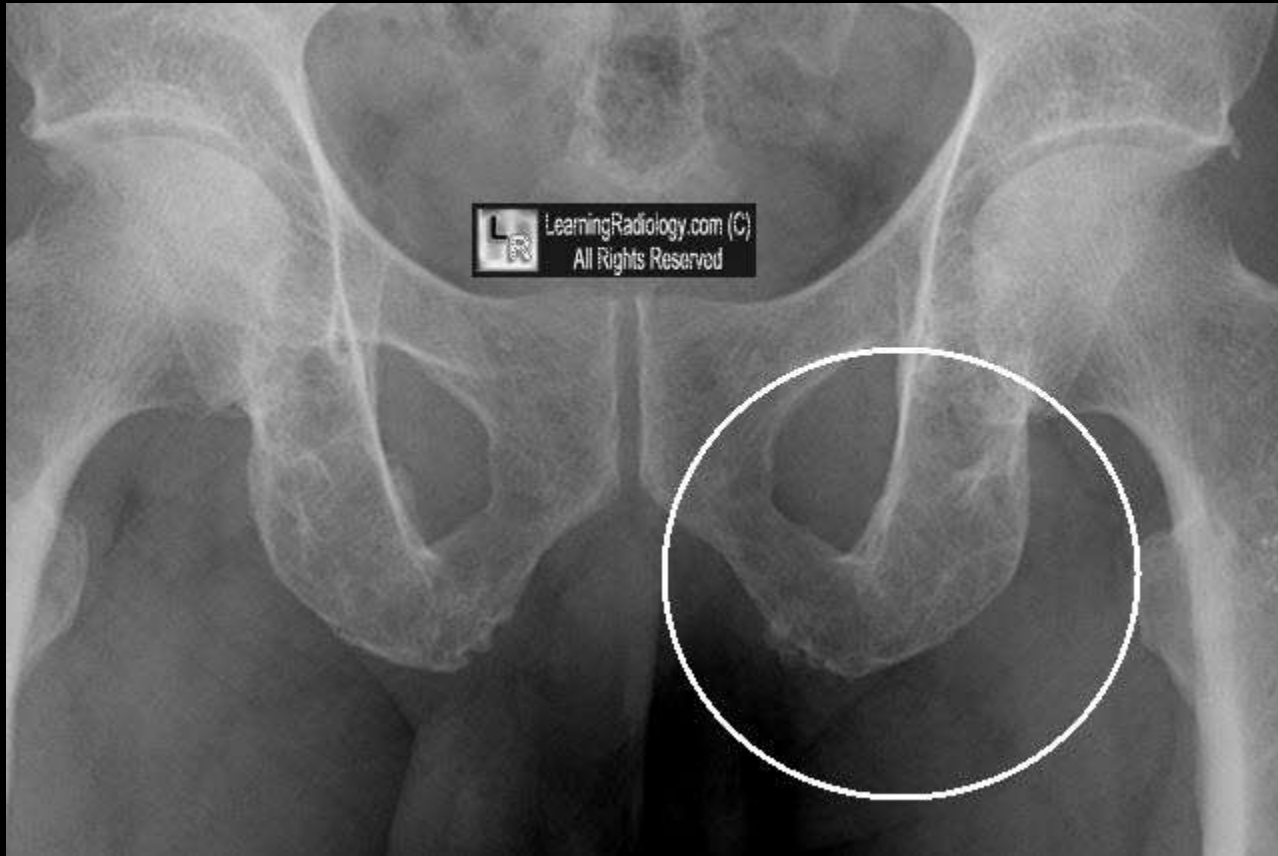
- *psoriatic erosions*
- in which *narrowed end of metacarpal* or phalanx inserts into *expanded end of adjacent bone*

Pencil Pointing



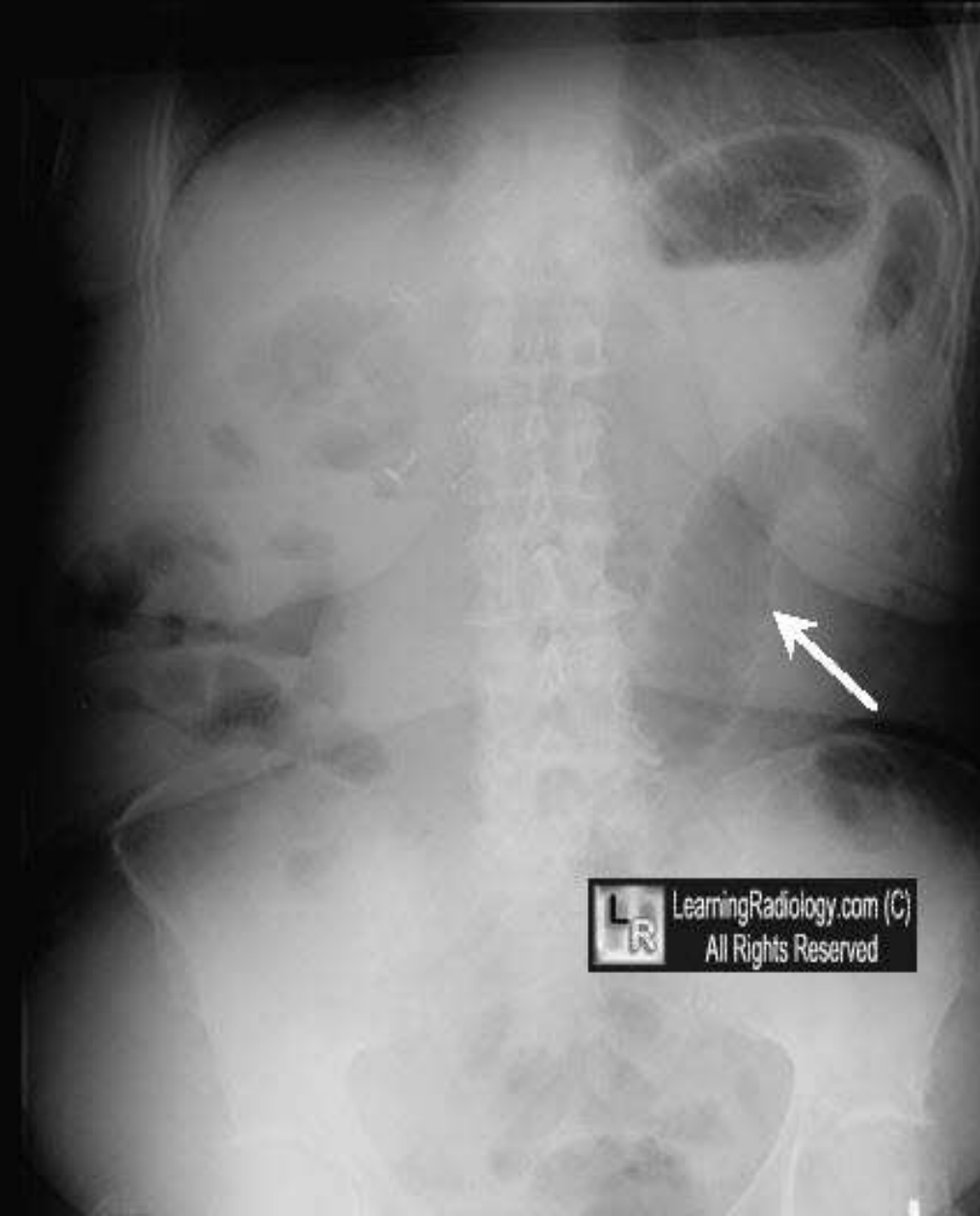- sharply tapered erosion of distal clavicle
- usually seen with rheumatoid arthritis

Soap Bubbly Appearance

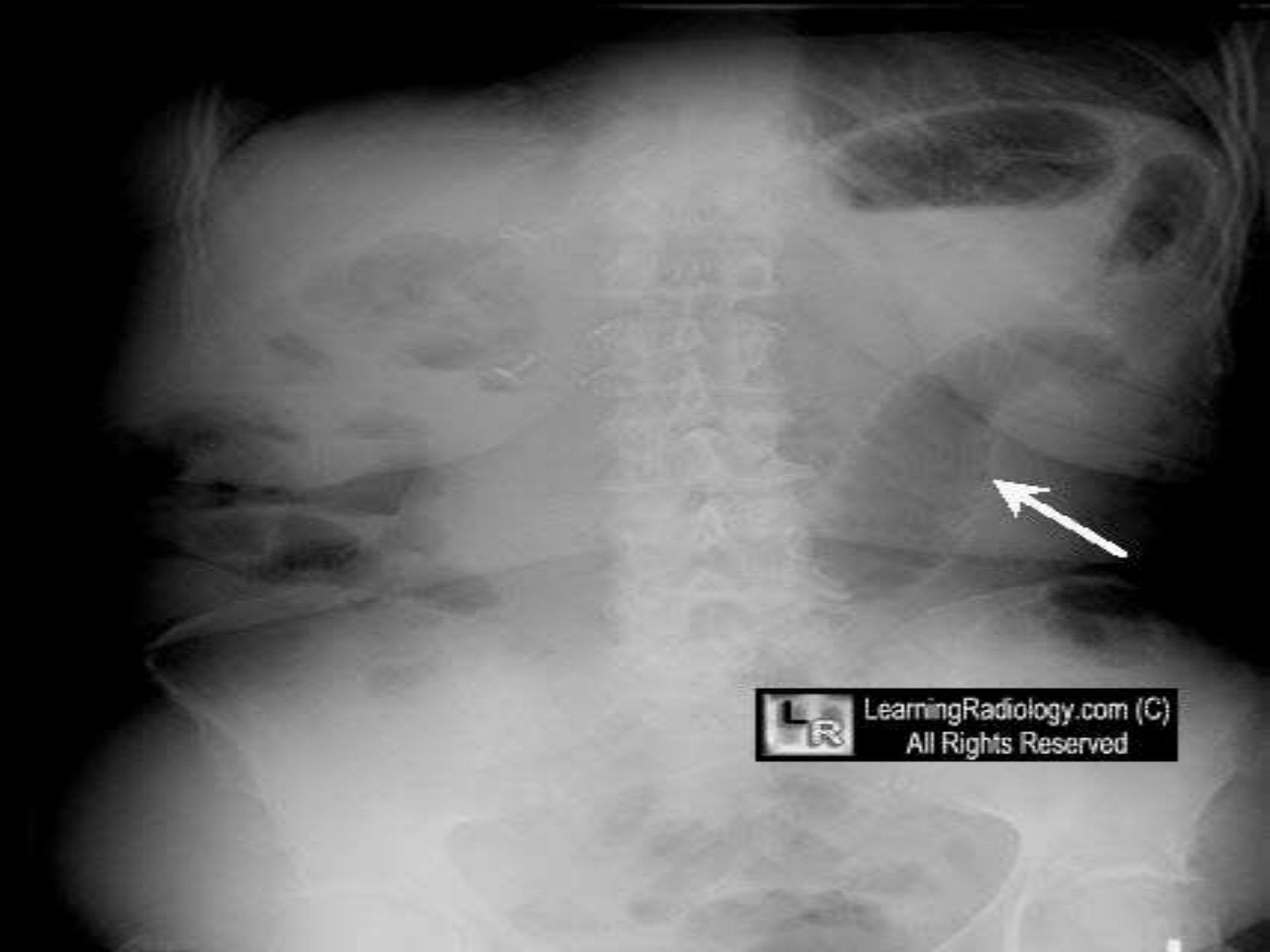


- **expansile, septated appearance of solitary plasmacytoma or renal or thyroid cell carcinoma metastases**

Sentinel Loop

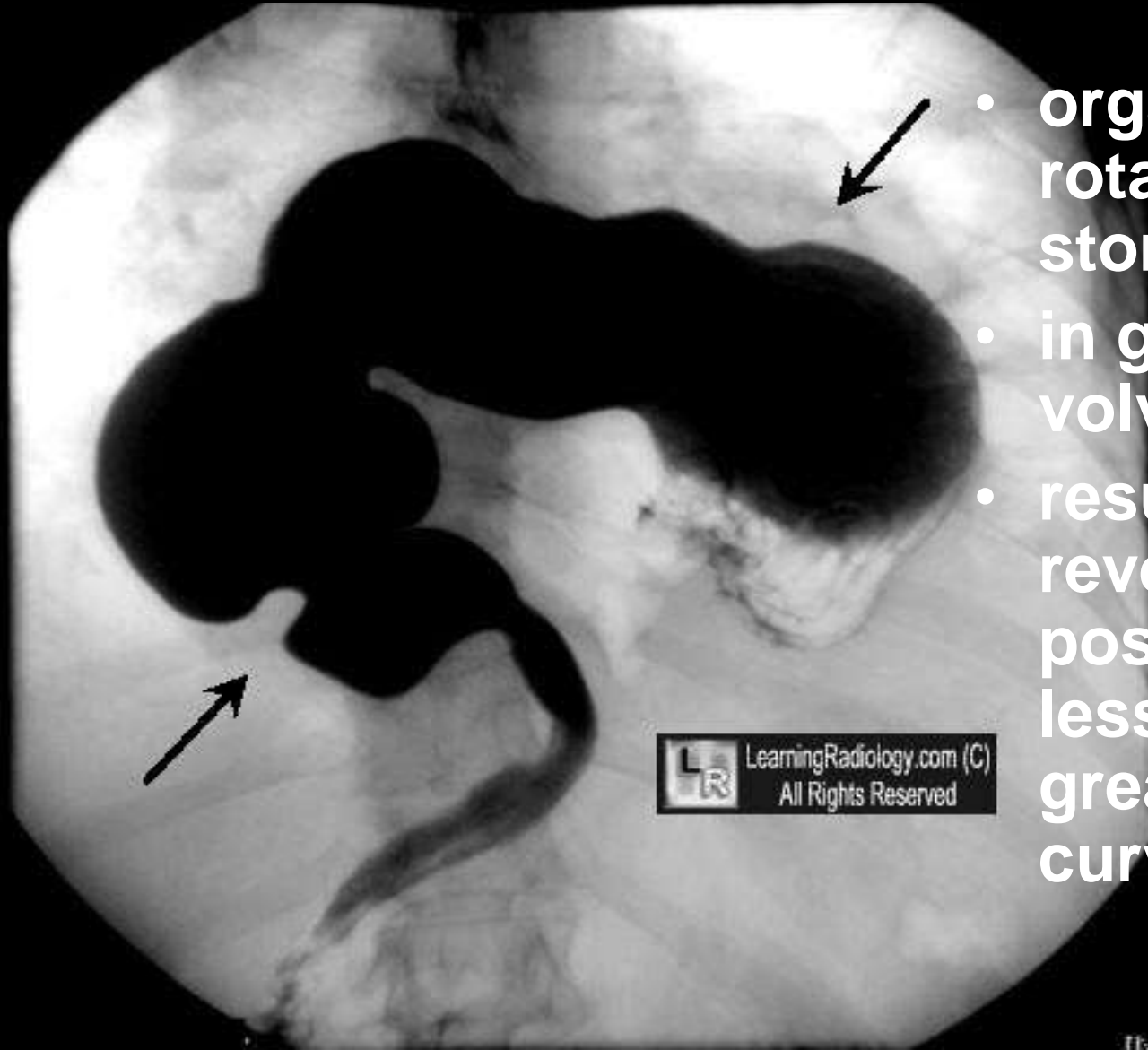


- one or two dilated loops of small bowel which may
- indicate the presence of an *irritative process* in the region, e.g., inflammation
- Sentinel = حارس



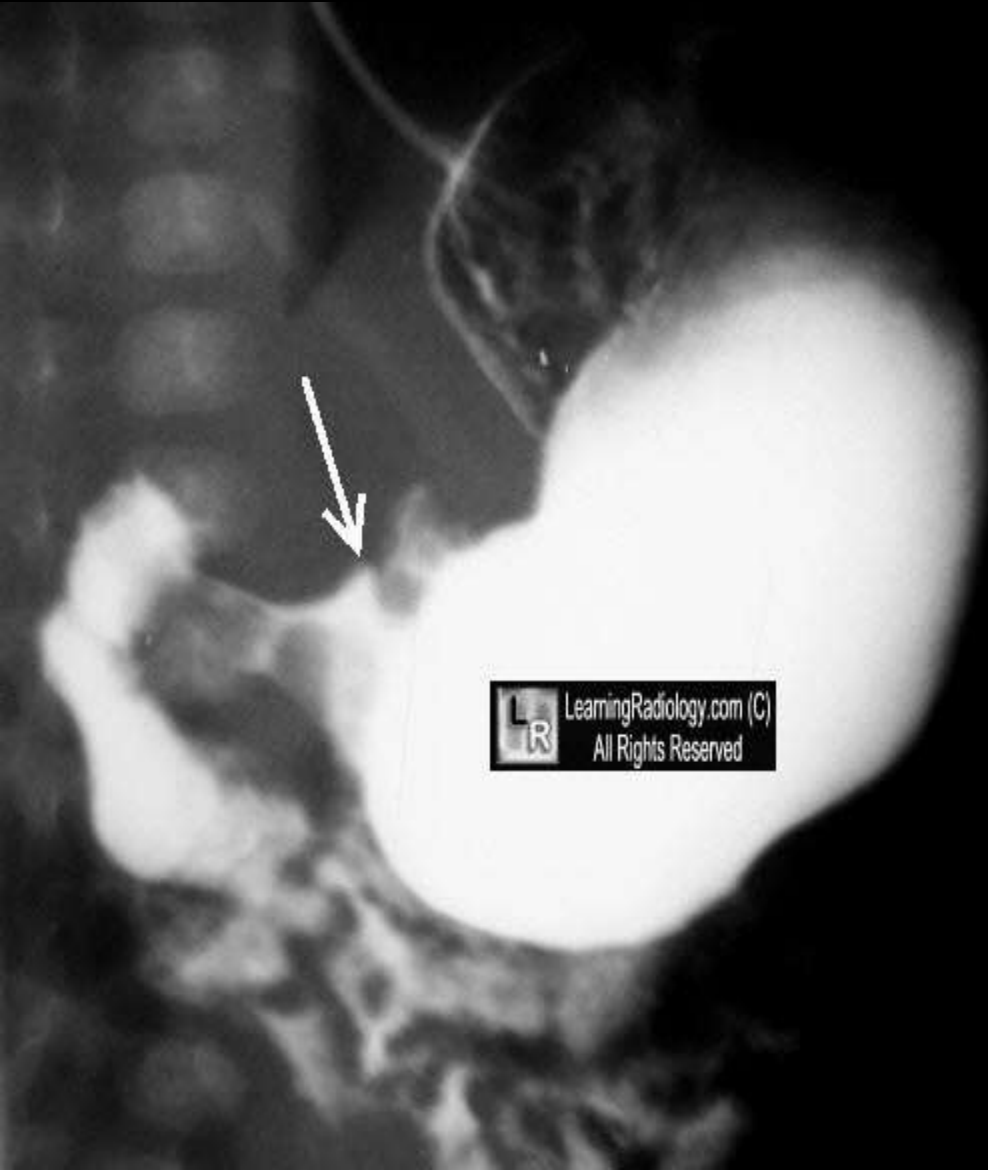LearningRadiology.com (C)
All Rights Reserved

Upside Down Stomach



- organoaxial rotation of stomach
- in gastric volvulus
- resulting in reversed positions of lesser and greater curvatures

Pyloric Tit Sign



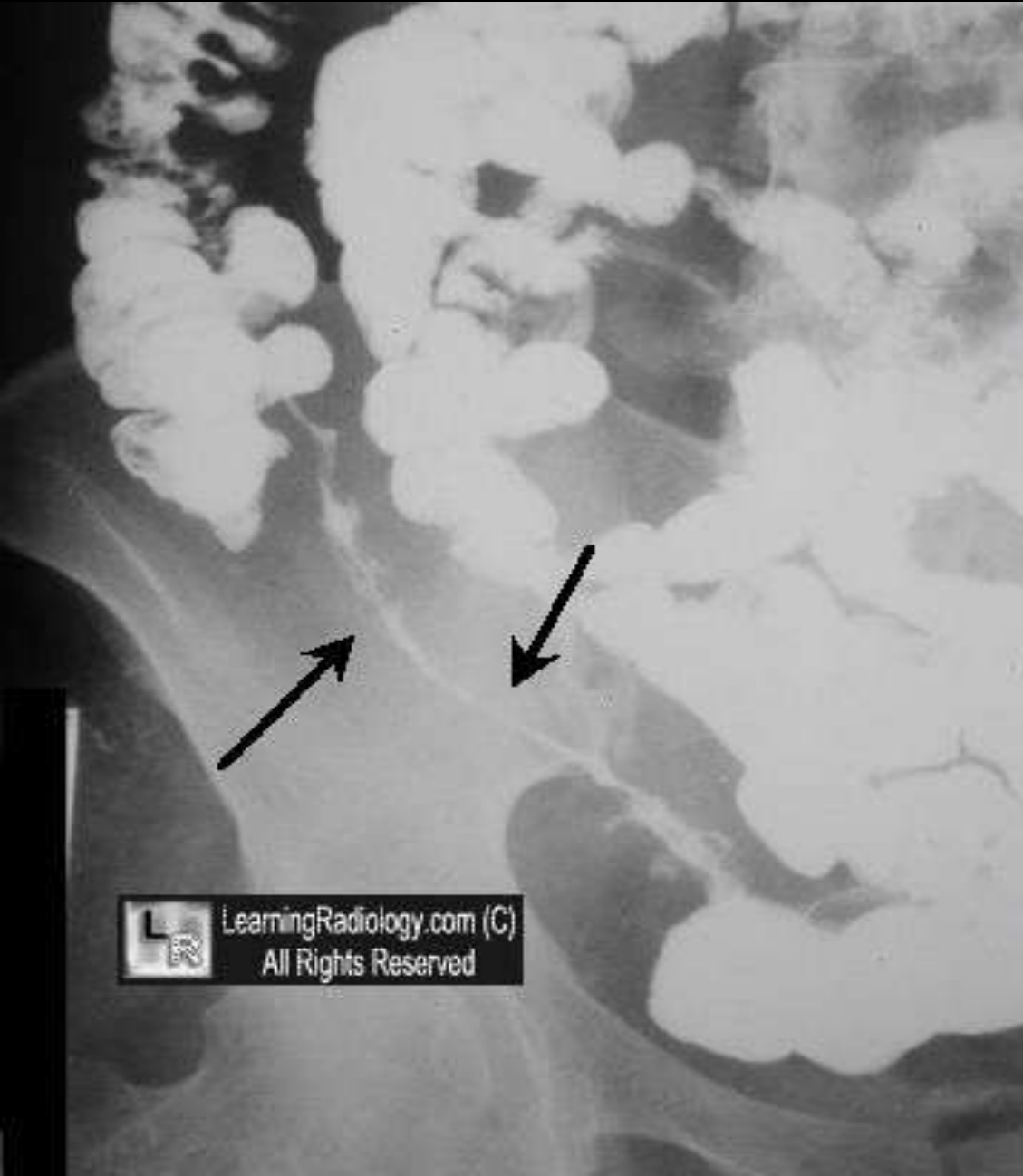- Out-pouching created on lesser curve
- By distorted muscle
- In hypertrophic pyloric stenosis

String of Beads Sign

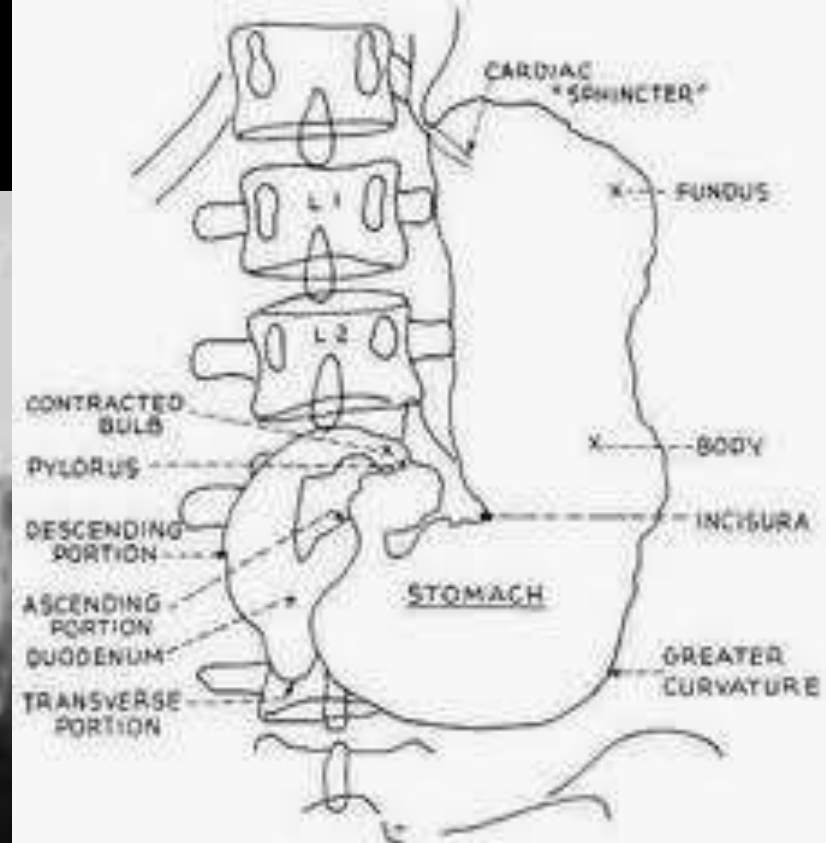
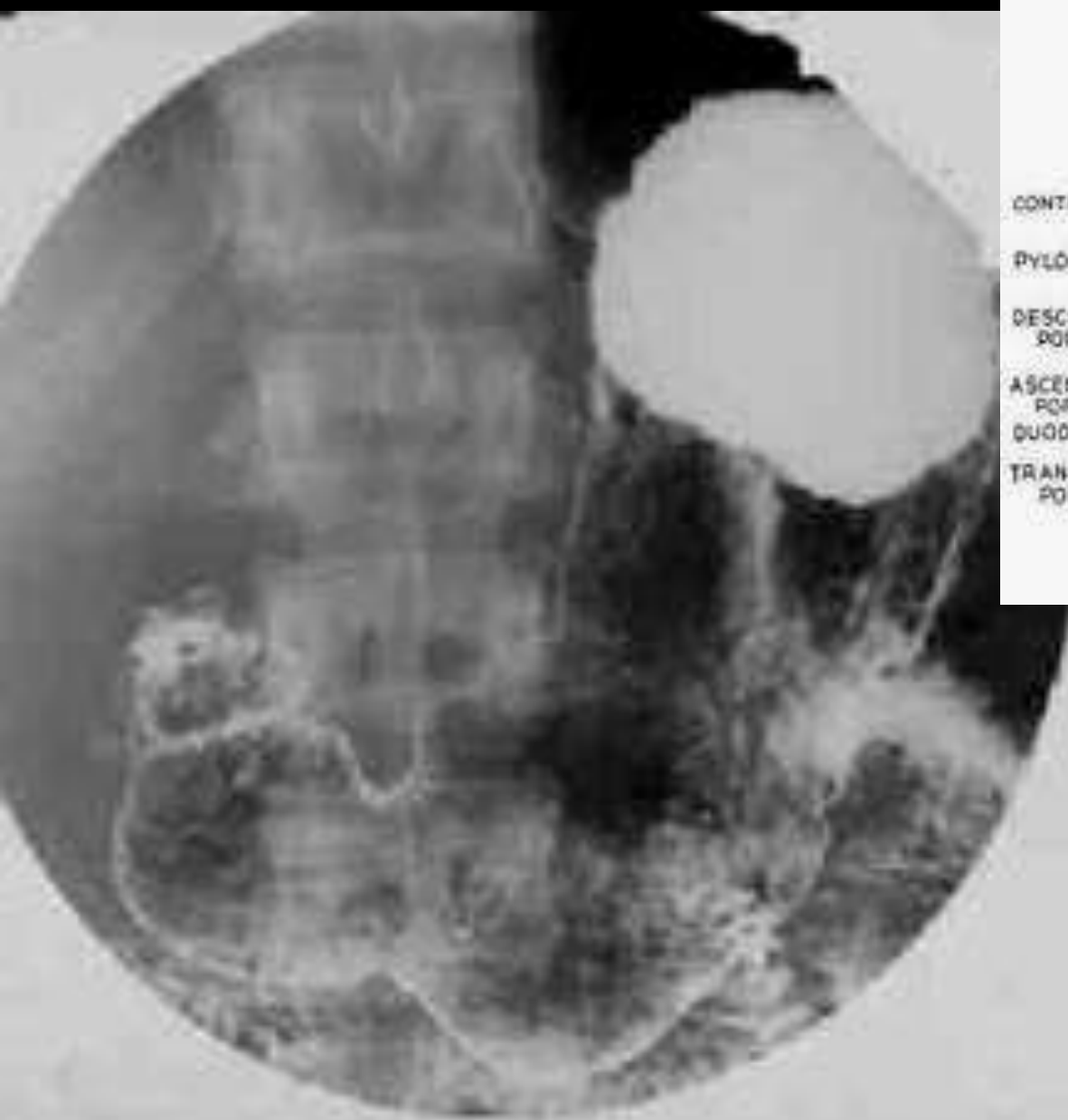

- multiple, linearly-arranged small pockets of air in a fluid-dilated small bowel loop
- seen with mechanical SBO

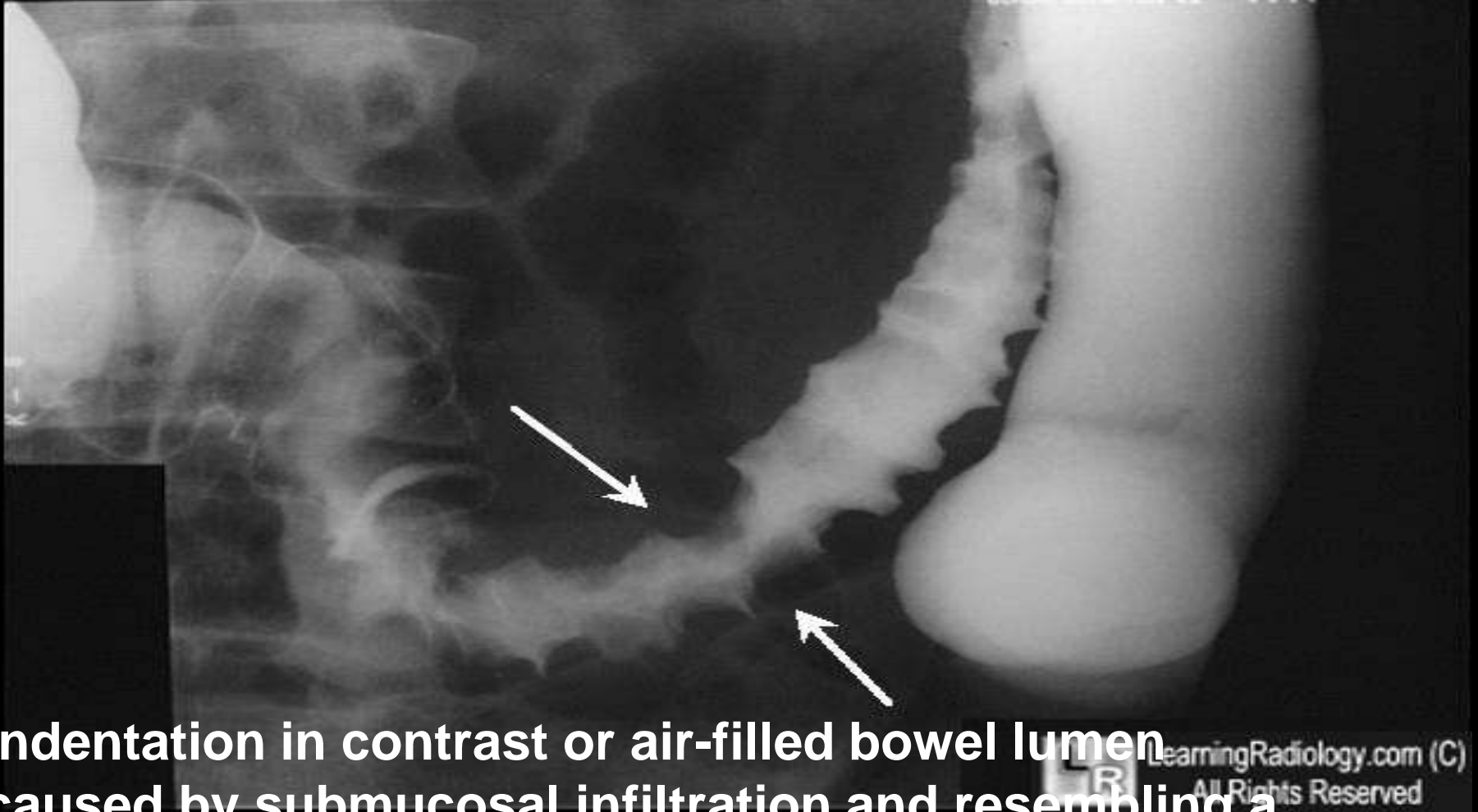
String Sign



- very thin luminal contrast
- usually in terminal ileum
- from spasm and eventually fibrosis,
- most often seen in Crohn disease
- String = سلك او وتر



Thumb-printing

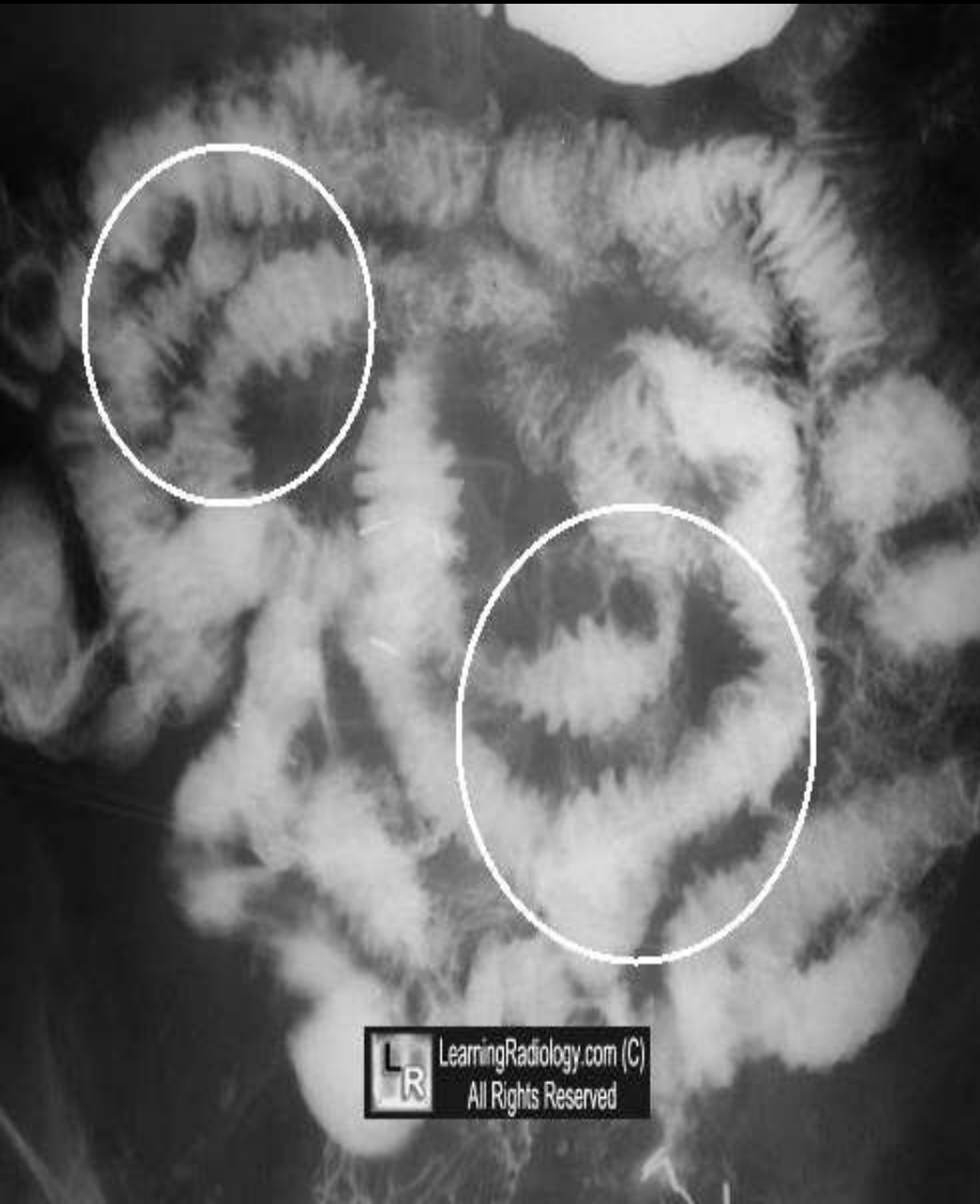

- indentation in contrast or air-filled bowel lumen
- caused by submucosal infiltration and resembling a Thumbprint
- eg ischemia

وتد المبارزة, Picket Fence

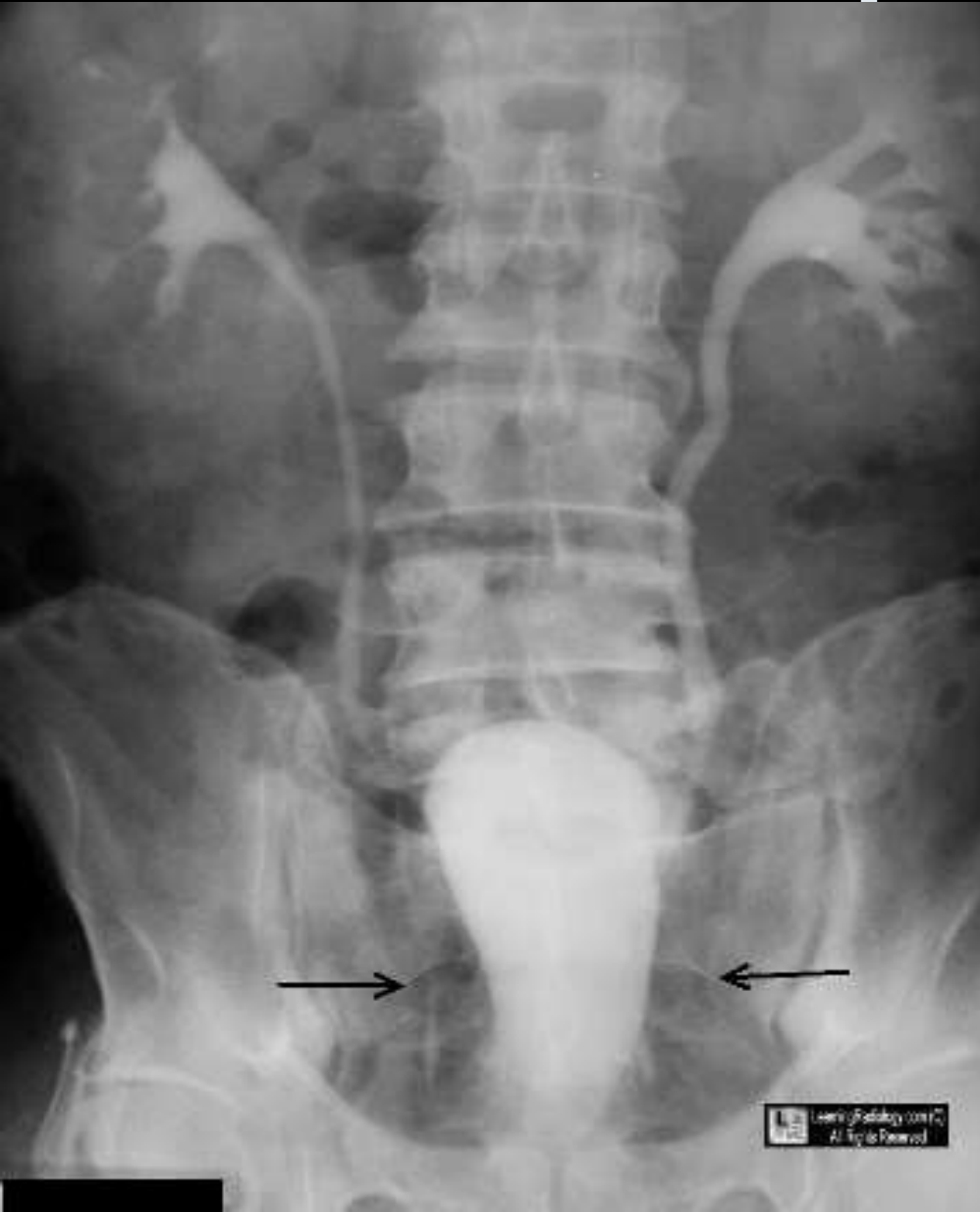

Picket Fence Appearance



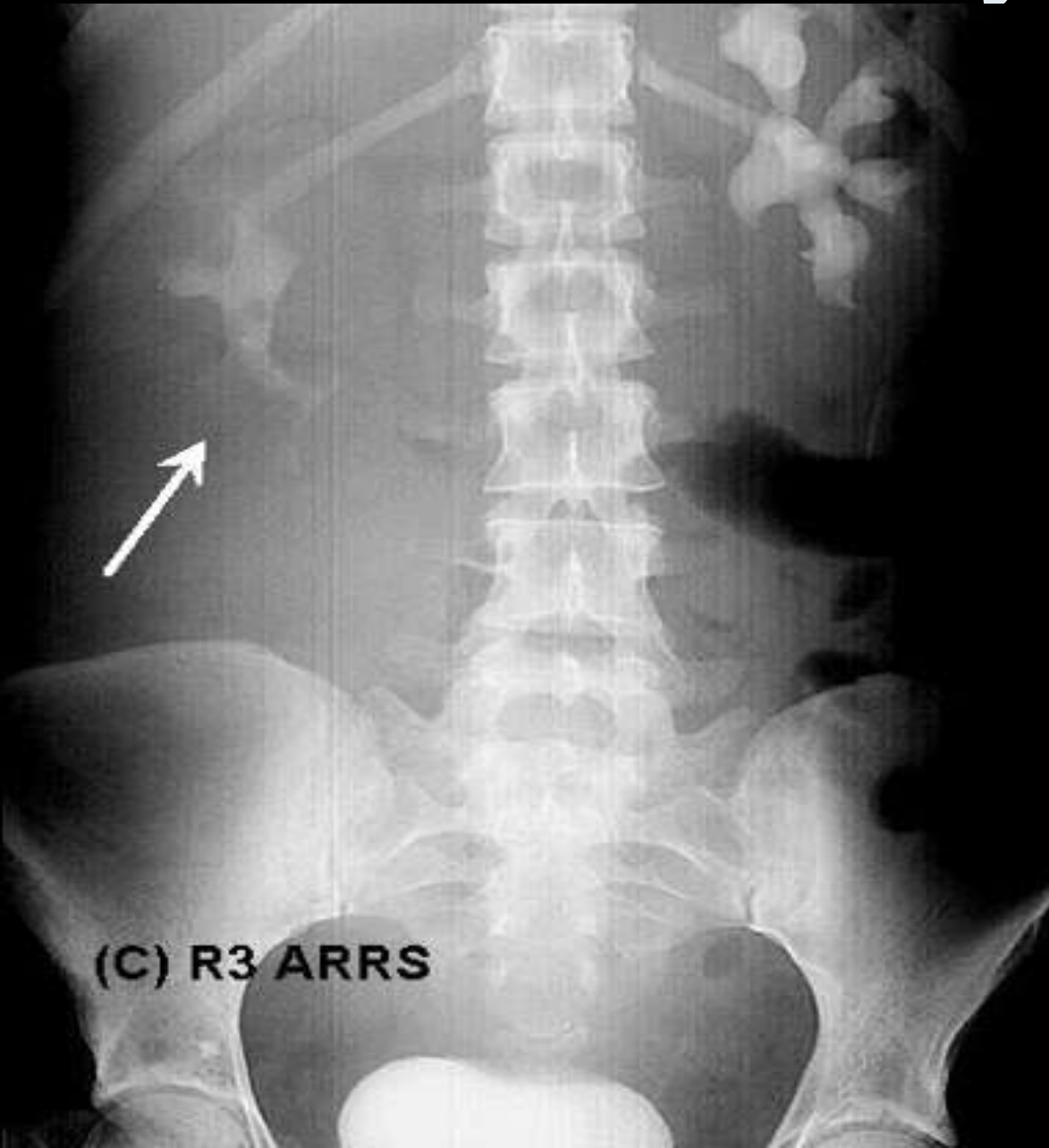
- **spiculated contour of small bowel with submucosal infiltration,**
- **as in hemorrhage or radiation**

Pear-shaped Bladder



- **shape of urinary bladder from extrinsic compression**
- **from excess pelvic :**
 - **fat, fluid, blood, urine or adenopathy**

Phantom Calyx Sign



- absence of an expected renal calyx
- from :
 - TB,
 - neoplasm or
 - stricture

THANK YOU